



## Case Reports

# Meckel's Diverticulum found on Virtual Capsule Endoscopy

October 8, 2015 [Case Reports](#), [October-December 2015](#)

**Keywords** [Meckel's diverticulum](#)

**Amar Mandalia, MD (1), Benjamin Hinrichs, MD (2), Tanvi Dhere, MD (3)**

Affiliations: (1) Emory University School of Medicine, Atlanta, GA (2) Department of Pathology and Laboratory Medicine, Emory University School of Medicine, Atlanta, GA

(3) Division of Digestive Diseases, Emory University School of Medicine, Atlanta, GA

### Corresponding author:

**Tanvi Dhere, MD**

Emory University Hospital

Atlanta, GA 30322

Phone: 404-778-2958

FAX: 404-778-2578

[tdhere@emory.edu](mailto:tdhere@emory.edu)

**Disclosures:** The authors have nothing to disclose.

### Author Contributions:

Dr. Amar Mandalia assisted in writing the case report. Dr. Hinrichs provided the pathology images along with descriptions. Dr. Tanvi Dhere assisted in editing/writing the case report.

### Case:

A healthy 39-year-old Caucasian male presented to an emergency department with three episodes of hematochezia over two days, along with a syncopal episode and diaphoresis. An upper endoscopy revealed mild esophagitis and a non-bleeding erosion in the duodenal bulb, and colonoscopy was unrevealing. Capsule endoscopy revealed an ulcerated diverticulum in the ileum (Figure A). A subsequent Meckel's scan (Figure B) with single photon emission computed tomography and pre-administration of cimetidine demonstrated activity in the right lower quadrant, likely in the ileum (, which indicated a Meckel's diverticulum (MD). He underwent a laparoscopic small bowel resection of the affected portion of the ileum, which on pathology was consistent with MD (Figures C and D).

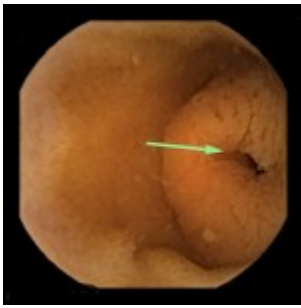

Figure A. Meckel's diverticulum on capsule endoscopy

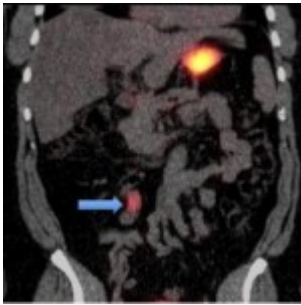


Figure B. Meckel's scan

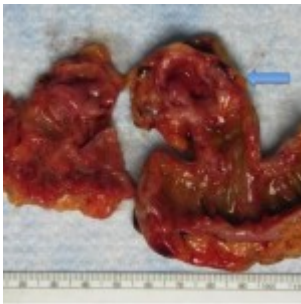

Figure C. Gross specimen

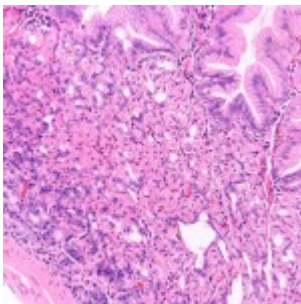


Figure D. Meckel's Histology

## Discussion

MD is the most common congenital malformation in the gastrointestinal tract, and is present in 2% of the population. MD mostly presents in the pediatric population, and is rare in adults. The most frequent complication in adults is bleeding, as in our patient; in children it is obstruction. Previous reports of identification of a Meckel's diverticulum with use of capsule endoscopy have been reported in the literature. We confirmed the diagnosis in our patient with use of a Meckel's scan. Our case highlights the utility of capsule endoscopy in the diagnosis of MD.

## Main Menu

- [About](#)
- [Current Issue](#)
- [Past Issues](#)
- [Goals](#)
- [Editorial Board](#)
- [Instructions for authors](#)

## Search

Search for:

## Links

- [Advanced Hospital Medicine Fellowship](#)
- [Physician Assistant Residency in Hospital Medicine](#)

Copyright © 2018 - The Curators of the [University of Missouri System](#).

All rights reserved. [DMCA](#) and [other copyright information](#). An [equal opportunity/affirmative action](#) institution.