

DOUBLE PELVIC OSTEOTOMY
FOR THE TREATMENT OF HIP DYSPLASIA IN DOGS

A Thesis presented to
the Faculty of the Graduate School
at the University of Missouri-Columbia

In Partial Fulfillment
of the Requirements for the Degree
Master of Science

by
JOHN P. PUNKE
Dr. Tony Mann, Thesis Supervisor

JULY 2011

© Copyright by John P. Punke, DVM, Diplomate ACVS 2011

All Rights Reserved

The undersigned, appointed by the dean of the Graduate School, have examined the
thesis entitled

DOUBLE PELVIC OSTEOTOMY
FOR THE TREATMENT OF HIP DYSPLASIA IN DOGS

presented by John P. Punke, a candidate for the degree of Master of Science and hereby
certify that, in their opinion, it is worthy of acceptance.

Professor F. A. (Tony) Mann

Professor James Tomlinson

Professor Derek Fox

DEDICATION

This thesis is dedicated to my family, my loving parents Charles and Rose Punke, my brothers and sisters, Elton and Joan Todd, Jacob, Joseph, and Jessie Punke, and my nieces and nephews Tyler, Elizabeth, and Candace Todd. Their incredible patience and unwavering support has been a quiet source of strength for me for the past 8 years while I've been away from home pursuing my higher education. I hope that my successes and achievements have justified their sacrifice. The comfort and joy that I bring to my animal patients and their owners over the course of my career will be done in my family's honor.

I also dedicate this thesis to Linzi Newth Punke, my intelligent, beautiful, and loving wife. Her love and attention has sustained me well over the past two years. I am a better man because of her. I will be forever grateful for having her in my life.

And finally, but most importantly, I must thank God for the infinite gifts, mercy, and love He has given to me. I would be nothing without Him.

ACKNOWLEDGEMENTS

I need to acknowledge and thank those who have helped me become the scientist and surgeon I am today. I hope to use what you have taught me to continue to grow and become the best surgeon I can be.

Dr. Tony Mann, as my residency and graduate program mentor, your example has taught me that with hard work, patience, prayer, and a firm moral standing, I can overcome what seem to be insurmountable obstacles. You have always supported me when others have doubted what kind of person I am. For that I will be forever grateful. I couldn't have asked for a better mentor.

Drs. James Tomlinson and Derek Fox, you are two of the best teachers, surgeons, and men I have ever known. I will carry your shining examples with me for the rest of my career. You have taught me that the best decisions, whether in the OR or in life, are rarely the easiest ones. I hope that my career will make you proud.

To my wonderful resident mates, Warnock, DD, Tink, Frenchie, Sammy, and Whitlock, I could have never finished the residency and become a surgeon without you guys. Our residency is a team effort, and you've been the best team I could ever ask for. Thank you.

I wish I had more room to personally thank by name all of the wonderful staff, technicians, faculty, and clients at the MU-VMTH. It is because of your patience, humor, and friendship that despite some hard times, I still loved coming to work every day. I will miss each and every one of you.

TABLE OF CONTENTS

ACKNOWLEDGEMENTS	ii
LIST OF FIGURES	v
LIST OF TABLES	vi
LIST OF ABBREVIATIONS.....	vii
ACADEMIC ABSTRACT	ix
CHAPTER	
1. Canine Hip Dysplasia and the Role of Pelvic Osteotomy as Treatment	1
Background	
Pathology of the Coxofemoral Joint with Canine Hip Dysplasia	
Etiology	
Genetic Influence	
Hormonal Effects	
Nutrition	
Diagnostics	
Medical Therapy	
Surgical Therapy	
The Case for Pelvic Osteotomy	
2. Acetabular Ventroversion with Double Pelvic Osteotomy versus Triple Pelvic Osteotomy: a Cadaveric Study in Dogs	28
Introduction	
Materials and Methods	
Results	
Discussion	

3. Retrospective Comparison of Complication Rates between Double Pelvic Osteotomy and Triple Pelvic Osteotomy at the University of Missouri	45
Introduction	
Materials and Methods	
Results	
Discussion	
4. Conclusions and Future Directions	59
REFERENCES	66

LIST OF FIGURES

Figure	Description
Figure 2-1	Photos from the craniolateral and caudal aspects of a mounted pelvis specimen
Figure 2-2	Lateral and dorsal views of a canine pelvis representing computed tomography slices
Figure 2-3	Computed tomographic image illustrating the acetabular angle
Figure 2-4	Line graph comparing the average acetabular angle values
Figure 2-5	95% confidence intervals for the concordance correlation coefficient
Figure 2-6	Photo of a mounted specimen after a double pelvic osteotomy of 30°
Figure 3-1	Bar graph comparing the ages and weights of clinical patients with Triple Pelvic Osteotomy or Double Pelvic Osteotomy
Figure 3-2	Bar graph comparing complication rates and outcome of clinical patients with Triple Pelvic Osteotomy or Double Pelvic Osteotomy
Figure 4-1	Photo of the New Generation Devices Double Pelvic Osteotomy Plate

LIST OF TABLES

Table	Description
Table 2-1	Anatomic Angle for Baseline and after Double Pelvic Osteotomy (DPO at 20°, 25°, 30°) and Triple Pelvic Osteotomy (TPO at 20°)
Table 2-2	Change in Anatomic Angle from Baseline after Double Pelvic Osteotomy (DPO at 20°, 25°, 30°) and Triple Pelvic Osteotomy (TPO at 20°)
Table 2-3	Change in Anatomic Angle Measurements between Successive Osteotomy Techniques
Table 3-1	Descriptive Data for Clinical Patients receiving a Triple Pelvic Osteotomy
Table 3-2	Descriptive Data for Clinical Patients receiving a Double Pelvic Osteotomy

LIST OF ABBREVIATIONS

20°DPO	double pelvic osteotomy performed with a 20° plate
25°DPO	double pelvic osteotomy performed with a 25° plate
30°DPO	double pelvic osteotomy performed with a 30° plate
20°TPO	triple pelvic osteotomy performed with a 20° plate
AA	acetabular angle
CdIs	caudal ischial angle
CHD	canine hip dysplasia
CF	coxofemoral
CPOP	canine pelvic osteotomy plate
CrIs	cranial ischial angle
CT	computed tomography
DCP	dynamic compression plate
DI	distraction index
DJD	degenerative joint disease
DPO	double pelvic osteotomy
EHR	extended hip radiograph
FHNE	femoral head and neck excision
IIcr	ilial crest angle
JPS	juvenile pubic symphysiodesis
MU-VMTH	University of Missouri Veterinary Medical Teaching Hospital
NGD	New Generation Devices
OA	osteoarthritis

PostAce	post acetabular angle
PreAce	pre acetabular angle
ST	sacroteruberous ligament
THR	total hip replacement
TPO	triple pelvic osteotomy

ACADEMIC ABSTRACT

DOUBLE PELVIC OSTEOTOMY FOR THE TREATMENT OF CANINE HIP DYSPLASIA

Introduction: Canine hip dysplasia (CHD) is the most common developmental orthopedic disease of dogs. It leads to coxofemoral joint osteoarthritis (OA) that can cause lifelong dysfunction and pain in affected individuals. Currently, there are several surgeries that can be performed in an effort to alleviate pain from CHD at various stages of the disease. Triple pelvic osteotomy (TPO) is a surgery that can be performed as early as 5 months of age and usually until 12 months of age, prior to the development of OA. Complication rates of 33-50% have been reported for TPO and have spurred interest in a newer technique, double pelvic osteotomy (DPO). The purpose of this thesis is to review the veterinary literature about CHD, surgical treatment options for CHD, and pelvic osteotomy in particular, describe an *in vitro* study to examine the acetabular ventroversion created by DPO compared to TPO, and a retrospective study comparing complications from TPO and DPO.

Methods: Cadaveric pelvises with intact sacroiliac joints were mounted in a custom jig. Computed tomographic images in the transverse plane were made of each pelvis at baseline, and after DPO at 20°, 25°, and 30°, and TPO at 20°. The pelvic angles were measured in six transverse planes. The values of each angle were compared for the three DPO techniques to the TPO via concordance correlation in order to determine which of the three DPOs results in the acetabular ventroversion angle closest to the TPO value.

The retrospective study was performed by evaluating all DPO and TPO cases with complete medical records at the University of Missouri and comparing patient

demographics, surgical details, major and minor complication rates, and outcomes between the two techniques.

Results: Average acetabular angles (\pm SD) in degrees were: Control (NoSx), 32.89 ± 2.23 ; DPO20, 47.39 ± 4.39 ; DPO25, 51.43 ± 5.06 ; DPO30, 54.75 ± 4.38 ; and TPO20, 50.20 ± 5.76 . Concordance correlations compared to TPO20 were: NoSx, 0.027; DPO20- 0.721; DPO25, 0.902; and DPO30, 0.593. A concordance correlation of ≥ 0.8 indicates good correlation.

In the retrospective study, TPO had 2 major complications (13.3% of cases), 7 minor complications (46.6%), and thus a 59.9% complication rate overall. Both major complications for TPO occurred in cases that had cranially malpositioned ilial osteotomies performed by unsupervised residents. The DPO cases had a 42.9% complication rate with all complications being minor in nature. Three minor complications from DPO potentially occurred as a result of under rotation of the acetabular segment.

Conclusions: Data from the *in vitro* study suggest that a 25° DPO results in the most similar acetabular ventroversion compared with the traditional 20° TPO, as indicated by a concordance correlation of 0.902. When performing the DPO technique clinically, the use of a 25° plate would be recommended in a patient that would have required a 20° plate previously with TPO.

The retrospective study found that DPO had lower major, minor and overall complication rates. DPO surgeries performed by faculty members with 30° plates and well positioned osteotomies had the lowest risk of complication. Osteotomy procedures

performed by residents, with 20° plates, malpositioned osteotomies, and TPO surgeries in general appear to be at higher risk for complication.

Chapter 1

Canine Hip Dysplasia and the Role of Pelvic Osteotomy as Treatment

Background

Canine hip dysplasia (CHD) was first described as an orthopedic disease in 1935.¹ It is now recognized as one of the most common developmental orthopedic conditions in the dog.²⁻⁹ In a retrospective survey over 5 years that included 2,885 dogs, it was found that 17.7% of mixed breed dogs and 19.7% of pure bred dogs with radiographs taken over that period had evidence of CHD.⁶ In Golden retrievers, prevalence in the entire population has been reported to be up to 74%.⁷ Canine hip dysplasia leads to secondary coxofemoral osteoarthritis (OA) that may cause discomfort, dysfunction, and decreased work longevity as early as 4 to 6 months of age and continues to progress with time.^{6,7,10-15} This progression of coxofemoral OA causes a decrease in the quality of life for companion animals and is a leading cause of retirement and euthanasia for research and military working dogs.^{16,17}

Since its first description over 76 years ago, the volume of research into the pathogenesis, potential etiologies, and methods for diagnosis and treatments for CHD has grown rapidly. Great progress has been made in some fronts as with total hip replacement as a definitive treatment, while other areas, like the underlying genetic basis for disease, still have much room for greater understanding.^{18,19} The goal of this chapter is to outline our current understanding of canine hip dysplasia as a disease, medical and surgical treatments for CHD, and the potential role of pelvic osteotomy in particular.

Pathology of the Coxofemoral Joint with Canine Hip Dysplasia

Dogs with canine hip dysplasia are born with phenotypically normal coxofemoral (CF) joints.²⁰ From birth to 8 weeks of age, dogs undergo a period of rapid growth and development.²¹ The soft, plastic tissues of the hip and pathologic laxity allow subluxation of the hip joint and stretching of the ligament of the head of the femur and joint capsule. The articular surface of the femoral head erodes where it contacts the dorsal rim of the acetabulum.²⁰ Progressive cartilage damage and erosion is the hallmark of degenerative joint disease (DJD). Damage to chondrocytes leads to an increased release of inflammatory mediators including interleukin-1, tumor necrosis factor, and stromelysin that overwhelm enzyme inhibitors that would typically prevent excessive inflammation and tissue destruction.²² Damaged cartilage also swells as exposed proteoglycans take on more water and alter its mechanical properties, leaving it more susceptible to traumatic shear forces. Microfracture of the subchondral bone causes trabeculae to harden thus decreasing the protective effect a softer subchondral bone has on articular cartilage.²³

These osteoarthritic changes can be seen grossly.

Because of the anatomy of the canine hip, the subluxated hip will put pressure on the dorsal acetabular rim causing continued wear of the articular cartilage of the femoral head and growth disturbance of the acetabular rim and pathologic blunting.²⁴ The acetabulum eventually takes on a shallow conformation and contributes less and less to the support of the ground reaction forces transmitted through the pelvic limb. Eventually, the joint capsule acts to transmit most of the forces to the pelvis. With shallow acetabular conformation, the joint capsule is stretched and torn from the dorsal acetabular rim

leading to osteophyte formation at the insertion of the joint capsule. On gross examination, joint changes can be seen as effusion of the joint, thickening of the joint capsule, stretching of the ligament of the head of the femur, fibrillation and eburnation of the articular cartilage and periarticular osteophyte production.^{24,25}

Clinically, osteoarthritic pain comes from vascular engorgement, microfractures, and collapse of the subchondral bone in the acetabulum and femoral head, and stretching and tearing of the teres ligament and CF joint capsule. Range of motion is lost by deformation of the joint surface and fibrosis and scarring of the periarticular soft tissue. The end result is the dysfunction and pain seen with osteoarthritis.^{24,25} The net effect of these biochemical, structural, and mechanical alterations leads to dysfunction of the entire joint, all its components and “organ” failure.²³

Etiology

So what then is the initiating factor that leads down this road to irreversible joint failure in predisposed dogs? This is the question that has prompted much debate and research in veterinary medicine and, if answered accurately and definitively, might possibly lead to the ultimate treatment for dogs with CHD.

In general, two theories about the etiology of CHD have been proposed, CF joint laxity and abnormal endochondral ossification. These two etiologies are most likely not mutually exclusive.²⁶ Since joints develop in growing animals in relation to the forces applied to them, it would stand to reason that if a joint had abnormal loads across them secondary to laxity, then cartilage formation would be affected secondarily. It would also

make sense that abnormal stresses on periarticular tissues would result in secondary laxity if the joint is primarily affected by abnormal cartilage development.

Of the two theories, joint laxity appears to be more popular. It contends that the periarticular soft tissues supporting the hip are weaker or more lax in dogs predisposed to CHD. There is some evidence that the teres ligament may be the primary supporting structure of the hip in dogs up to one month of age, though its relationship in the development of CHD has not been studied.²⁰ The collagen content and composition of the joint capsule has been shown to correlate with its relative strength.²⁷ Dogs with CHD have also been shown to have weaker joint capsules with more collagen type III and less collagen I than normal dogs.²⁸ This finding may represent a change secondary to the development of coxofemoral DJD. However, it has been shown that collagen type III:I ratios in people do not change during their adult life.²⁹ If dogs are similar, then differences in collagen type ratio may be a cause of joint capsule weakness and thus laxity in dogs predisposed to CHD.

Pelvic muscle mass has been studied in relation to CHD as well.³⁰ When compared to greyhounds (a breed virtually devoid of CHD), German shepherd dogs and mixed breed dogs had significantly less pelvic muscle mass expressed as a ratio of pelvic muscle weight to total body weight. When controlling for breed, significant differences were found between normal and affected individuals for both the German shepherd dogs and mixed breed dogs. Affected dogs had smaller quadriceps, sartorius, iliopsoas, adductor magnus et brevis, gracilis, pectineus, middle gluteal, semimembranosus, and quadratus femoris muscles. Muscle size correlated with the pathologic severity of CHD.³⁰ Histology and fiber type staining was performed on these dogs at 8 weeks of age

and found that individuals predisposed to CHD had smaller type-1 and type-2 fibers than normal dogs. This size discrepancy indicated pectineal hypotrophy, a developmental neuropathy in dogs predisposed to CHD.³⁰ These findings were very similar to those in rats that had neonatal neurectomies of the sciatic nerve.³¹ This evidence supports the idea that CHD was secondary to an underlying muscular defect rather than muscular disuse atrophy secondary to the pain of CF osteoarthritis.

Joint laxity may be a secondary change of CHD as well. Synovitis, joint effusion, and capsular edema have been shown to be early inflammatory changes with osteoarthritis and CHD in particular.^{32,33} As the joint capsule distends, this increases the intraarticular volume of fluid and has been shown to increase the degree of hip joint laxity as well.³⁴

While the pathogenic origin of CF laxity in dogs with CHD compared to its role as a secondary change as a result of osteoarthritis has not been completely elucidated, the presence of laxity in dogs with CHD has been clearly demonstrated.^{11,35} Laxity as measured by a radiographic distraction index (DI) score can be detected as early as 4 months of age, and the degree of laxity at 8 months of age is an accurate predictor of CHD at adulthood.³⁵ It has been shown that quantification of the degree of CF laxity by DI score can be valuable in making recommendations for early treatment for CHD, and predictive of the benefit of performing early intervention to slow the progression of CHD.³⁶ A more thorough discussion of diagnostic tests for CHD is included later in this chapter.

A second theory to explain the etiology of canine hip dysplasia cites abnormalities in endochondral ossification of the CF joint. In the development of the canine

acetabulum, the final bony structure is formed from three separate ossification centers and growth plates of the ilium, ischium, and pubic bones.³⁷ Canine hip dysplasia may be the result of abnormalities in this complex process. The earliest radiographic sign of CHD reported is a lag in ossification of the craniodorsal aspect of the acetabular rim.²⁰ Delayed ossification in the hip joints of dysplastic human infants has been reported.³⁸ A similar finding in dogs has also been demonstrated by a decrease of radionuclide uptake by the CF joints of young dysplastic dogs.³⁹ It has also been shown that mineralization of the proximal femoral epiphysis and closure of the femoral capital physis both occur significantly later in dogs with CHD compared to normal controls. Interestingly, the proximal tibial epiphysis also had significantly delayed mineralization, indicating that abnormal endochondral ossification in dogs with CHD may occur in other joints as well.⁴⁰ Although, this study failed to identify early closure of the triradiate acetabular growth plate as a cause of CHD in contrast to a previous nutritional study of Great Dane puppies.⁴¹

Genetic Influence

Many studies have documented the hereditary nature of CHD.^{2,3,42,43} The mode of inheritance is known to be polygenic and it is thought that a number of the major genes are recessive in nature.⁴⁴ Overall, heritability of hip phenotype is thought to be low.⁴⁵ This complicated mode of inheritance makes it possible for phenotypically normal breeding animals to be carriers of the disease. Additionally, mildly affected animals can be clinically normal during their breeding years. Complicating the matter further, environmental factors including nutrition and rate of growth are also known to play a role

in the development of disease.⁴⁶ Even if it were easier to identify individual carriers of CHD, as the prevalence of a disease in a population decreases, further genetic improvement becomes more difficult and takes longer to achieve.⁴³

Despite these challenges, breeders have made genetic progress to decrease the incidence of CHD in their populations. In less than 5 generations, the incidence CHD in a group of German shepherd dogs decreased from 55 to 24%, and from 30 to 10% in group of Labrador Retrievers. These dog breeders, in an effort to create high genetic selection pressure, used subjective hip scores as assigned by a radiologist to select the parents of the next generation of dogs.¹⁹ On a larger scale, in a study of over 250,000 Labrador retrievers, a 17% improvement in hip phenotype was observed by merely measuring and reporting individual dog's phenotypes for reference for breeding.⁴⁵

As one can see, knowledge of the genetic basis of CHD has allowed dog breeders to decrease the prevalence of CHD in their offspring by selective breeding. But because of the inheritance pattern and environmental influences that seem to affect CHD phenotype, there is still plenty of room for improvement. Recently, the fibrillin-2 gene has been found to be associated with CHD and development of secondary osteoarthritis.⁴⁷ Further research into this gene and others may help to develop a genetic test for CHD long before clinical signs occur and to aid in selection of breeding animals that might otherwise be phenotypically normal. However, until these tests become available, more sensitive screening tests are needed to identify mildly affected individuals.

Previously, individual tests including the extended hip radiograph (EHR), DI score, Norberg angle, and dorsolateral subluxation score have been used individually in an attempt to diagnose and assess the severity of CHD.^{13,26,48,49} However, the individual

heritability of each of these diagnostic tests alone has been disappointingly low from 0.10 to 0.68.⁵⁰ When using a combination of these tests to create a selection index that accounts for both hip laxity and secondary osteoarthritis, a much better ability to enforce genetic pressure has been proposed.² Exerting maximal genetic pressure to change population phenotypes is crucial to our current ability to use genetics to reduce the incidence of CHD in canine populations and will be expounded upon further in the chapter in the discussion on diagnostic techniques.

Hormonal Effects

A hormonal influence on the development of the musculoskeletal system of companion animals has been documented.⁵¹⁻⁵⁴ Gonadectomy does not affect growth rates, but physeal closure is delayed.^{51,52} Neutered male cats in particular have a 13% decrease in radial length compared to intact females.⁵² Neutered male cats are at increased risk for capital femoral physeal fractures as well. This risk is probably due to the delay of physeal closure until well over a year of age, and a propensity for obesity after castration.^{53,54} In examining the effects of gonadectomy on CHD in particular, the evidence is weak. One study found that neutered male boxers are 1.5 times more likely to develop CHD than their sexually intact counterparts. However, this study did not take body weight, body condition score, or age at neutering into consideration.⁵⁵ Another study of puppies neutered at 5.5 months of age had a 6.7% incidence of CHD compared to 4.7% when castrated at 1 year of age. The authors speculate that an increase in bone length and delayed physeal closure could account for the increased risk of CHD.⁵⁵

Maternal hormonal factors that may influence the development of CHD have been identified as well. Canine milk and colostrum differ from that of human and bovine species in that insulin, cortisol, epidermal growth factor, relaxin, estrogen, and estrogen precursors are found in significant quantities in canine milk and colostrum.^{56,57} These hormones are readily absorbed by the gastrointestinal tract especially early in the postnatal period.⁵⁶ Relaxin persists for only 1 to 2 weeks in the serum of normal Labrador bitches, while it persists throughout lactation in dysplastic bitches.⁵⁸ Relaxin, in particular, exerts effects on connective tissues to cause relaxation. It is also a potent inducer of matrix metalloproteinases I and III and plasminogen-activator expression.⁵⁹ Theoretically, the combined actions of relaxin could degrade extracellular matrix and negatively affect the structure and function of periarticular tissues leading to developmental hip laxity and CHD. This theory has been supported in the laboratory as well. Experimental inhibition of 17β -estradiol formation from birth throughout lactation significantly reduced hip joint laxity at maturity in Labrador retrievers predisposed to CHD.⁵⁸ Perhaps the hormonal etiology of CHD is currently poorly researched and under exploited. To date, there are no diagnostic tests or clinical treatments to screen for CHD in bitches or prevent the development of CHD in puppies that take advantage of these findings.

Nutrition

Nutrition has been shown to influence the incidence and progression of osteoarthritis secondary to CHD. Excesses of carbohydrates, protein, and vitamin C have all been implicated with varying levels of evidence.

In an early study, an increased incidence of CHD was found in Great Dane puppies that were intentionally overfed a diet rich in calories, protein, calcium and phosphorus. However, this study was not well controlled.⁴¹ A later study found that German shepherd dogs with rapid weight gain during the first 60 days of life were more likely to develop CHD.⁶⁰ Other studies have implicated rate of weight gain from 3 to 8 months of age as being more critical in the normal development of the CF joint.⁶¹ More recently, a well controlled, life-long study of dogs was conducted in which the test group was fed 25% fewer calories than those fed ad libitum. The restricted intake group had a 67% reduction in coxofemoral OA at 2 years of age and a lesser severity of OA at 5 years of age compared to control.⁶²⁻⁶⁵ In parallel with failure of endochondral ossification as an etiology for CHD, one study found that the growth plates of the acetabula of dogs on restricted diets fused later (7 months of age) than those of rapidly growing puppies (5 months), compared to normal closure at 6 months of age.⁶⁶ This study illustrates nicely the intersection of genetics and environmental factors (nutrition) in the development of CHD as a multifactorial disease.

While there seems to be good evidence that overfeeding and growth rate is a factor in the development of CHD, other nutritional factors, though implicated, bear much less proof.

Carbohydrates have been implicated, but have been found to not be a significant factor except in relation to caloric intake.⁶⁷ Despite multiple studies, protein does not seem to be an important nutritional factor either.^{61,67,68} One study found that large doses of vitamin C fed to pregnant bitches, then to the puppies seemed to be protective for CHD. However, this study did not appropriately follow the offspring with diagnostics for

any significant amount of time, potentially committing a type II error.⁶⁹ Finally, calcium is tightly regulated in the body as an important cofactor in a variety of processes including osteosynthesis.⁷⁰ Young, growing animals have a decreased ability to closely regulate calcium absorption from the GI tract and thus protect themselves from oversupplementation.⁷⁰ Many developmental orthopedic diseases in dogs have been linked to calcium oversupplementation including osteochondrosis, premature closure of the distal ulnar physis, and retained cartilaginous cores.^{41,71} However, CHD, specifically, has not been implicated as a side effect of high calcium intake.

In summary, nutrition, and overfeeding in particular, certainly plays a role in the development of hip dysplasia in dogs. However, nutrition in its nature is multifactorial and seems to play a small role in the multifactorial disease of CHD.

Diagnostics

The clinical presentation of hip dysplasia has a bimodal distribution. Clinical signs appear in puppies 5 to 9 months of age, or as mature adults.⁷² Even before this time, the diagnosis of CHD and predisposition to secondary OA can be made using a distraction index at 16 weeks of age.¹⁴ On physical examination, young dogs with early CHD may have pain with hip abduction or extension, or a positive Ortolani sign.^{73,74} However, some dogs are not diagnosed as puppies, but are diagnosed as adults many years later. The earlier a puppy is diagnosed with CHD, the more options there are available for treatment. For example, it is recommended that juvenile pubic symphysiodesis (JPS) be performed between 16 and 20 weeks of age, and the pelvic osteotomy techniques are most often performed before a year of age.⁷⁵⁻⁷⁸ As a

requirement for these two techniques, secondary OA cannot be present since the goal of these therapies to prevent osteoarthritic changes in the CF joint. Complicating the matter further is the fact that some dogs with CF subluxation will not have radiographic changes of secondary OA until after 2 years of age.⁷⁹ Therefore, it is important that the surgeon be reasonably certain that CHD will progress to OA in the patient prior to subjecting them to invasive surgery. The role of the diagnostic tests for CHD is to screen patients prior to the development of OA in their adulthood so that either surgical intervention can be performed as a preventative measure early in the disease process, or CHD can be diagnosed prior to breeding. Diagnostic techniques have been developed over the years in an effort to achieve these goals.

Palpation Techniques

The Ortolani and Barlow signs were developed for the early identification of congenital hip dysplasia in newborn babies and have since been reinterpreted for veterinary use.^{74,80} Bardens and Slocum developed other palpation techniques strictly for veterinary use.^{81,82} Very little has been published in the peer reviewed veterinary literature evaluating these techniques in their ability to predict the development of OA in dogs with CHD.⁸³ One study found that the Ortolani sign was moderately associated with hip laxity as seen on distraction radiography. The same study found that 33% of dogs graded “good” by the Orthopedic Foundation for Animals had a positive Ortolani sign.^{84,85}

Extended Hip Radiograph

In 1961, the American Veterinary Medical Association established the diagnostic criteria for CHD. They recommended the extended hip radiograph, taken with dogs in dorsal recumbence with stifles internally rotated, and hips fully extended, as a screening tool to evaluate pelvic anatomy and secondary changes associated with coxofemoral OA.⁸⁶ This technique has been adopted by numerous organizations that apply a variety of scoring methodologies to grade the pathology seen in this view.^{87,88} The diagnosis of CHD is made based on visualization of hip laxity or secondary changes associated with OA, or both. Typical changes include periarticular osteophyte production on the femoral neck or acetabular margin, subchondral sclerosis of the acetabulum, and secondary joint changes from chronic wear.⁸⁸⁻⁹¹ Since radiographic evidence of OA occurs at the end stages of disease, and some dogs may not have any secondary OA until 2 years of age, the extended hip radiograph has proven itself to be an insensitive technique for the early diagnosis of CHD.^{85,92} The desire to screen breeding animals for CHD at a young age and to diagnose and treat CHD early in the course of disease has prompted research into more sensitive tests for canine hip laxity.¹¹

Distraction Index

Multiple techniques have been developed to evaluate for canine hip laxity including the dorsolateral subluxation score and Norberg angle.^{26,84} However, the test that has had the best correlation between subjective scoring and the development of OA has been the DI score.^{85,93}

The DI score is a calculated measure made from two stressed ventrodorsal radiographic views of the pelvis with both femurs compressed into the acetabula in one view and distracted from the acetabula in another. The resulting calculation is a score from 0 to >1 that represents the relative laxity of the soft tissues supporting the CF joint. A score of 1 would indicate complete luxation of the joint.¹⁰ Based on a large database of scores, the typical range of scores by breed has been published so that breeding animals can be selected that would help decrease the incidence of CHD in their breed.⁷ On an individual basis, individuals with scores of <0.3 are considered to be protected from developing OA secondary to CHD, while those with scores >0.7 have a 90% risk of developing OA.¹⁴ It has been shown that only 1.5% of dogs with DI scores of <0.3 develop OA secondary to CHD later in life.¹¹ Individuals between these values have varying risks for OA depending on their breed and environmental factors.⁷ In one study, 51% of dogs with DI scores over 0.3 developed OA.¹¹ The DI score has the advantage of diagnosing CHD as early as 16 weeks of age and having good repeatability when performed again at 24 months of age.¹¹ A very recent study has shown that DI score can be prognostic for young dogs undergoing early intervention with a JPS when done at 16 weeks of age. Puppies with DI scores less than 0.6 had excellent results with the procedure, those from 0.61-0.75 had fair to good results, while those greater than 0.75 had poor results or worse.³⁶ These results and the volume of research behind the DI score have made it the most ideal technique for early screening of CHD in breeding animals and in the evaluation of patients for early surgical intervention for the prevention of secondary OA.⁸⁵

Medical Therapy

Since CHD is known to be a multifactorial disease, any genetic influence on anatomy cannot be expected to be treated entirely through medical management.^{43,72,94,95} However, the nutritional, activity related, and, perhaps in the future, the hormonal influences on disease may be treated through medical therapies.^{95,96}

With the bimodal timeframe for CHD clinical signs, it has been shown that puppies showing clinical pain at 5 to 6 months of age may become more comfortable with restricted activity alone.³⁷ In one study, 63% of puppies that had hip pain associated with CHD had no pain on forced hip extension on reevaluation 4.5 years later.⁹⁷ This study, however, did not evaluate dogs radiographically or follow them into their geriatric years to screen for the presence of OA and lifelong dysfunction. This lack of follow up exposes the study to a high risk for type II error. The fact that 37% of dogs did not have resolution of pain is also disheartening. And, even though puppies' comfort may improve in the short term, OA as a progressive disease can be expected to cause clinical difficulty in the future.⁹⁸ Dogs diagnosed with CHD at a young age can be expected to have daily clinical manifestations of the disease in 66% of cases and CF pain on physical examination in 98% of cases.⁹⁸

Another study has shown that intramuscular injection with polysulfated glycosaminoglycans decreased subluxation in puppies predisposed to CHD, but has not been substantiated since.⁹⁹ The treatment that has shown the most promise in decreasing OA secondary to CHD has been dietary restriction. In a lifelong study, hip OA was decreased in prevalence by 15% at 2 years and 67% over the life span in dogs restricted to 75% of food intake compared to the control group fed ad libitum.¹⁷ However, it seems

the role of medical management of CHD is to help control secondary OA, rather than prevent its occurrence. With the advent of cyclooxygenase-2 selective nonsteroidal anti-inflammatory drugs and other advanced analgesics, physical therapy, and nutraceuticals, veterinary medicine has made great strides in the treatment of osteoarthritic pain.^{100,101} In fact, a recent study found that during the 2000s dogs with CHD were having total hip replacement surgery at a later age and after longer periods of medical management than those from the 1990s. The authors speculated that improved medical management of canine OA is a cause for this delay.¹⁰² Multiple studies have shown that in order to prevent OA from CHD, surgical intervention is needed.^{36,103}

Surgical Therapy

The ideal surgery for CHD would be minimally invasive, easily performed, inexpensive and would not have any adverse effects for the patient or age related constraints. While there have been many surgeries proposed as treatments for CHD, none have met all of these criteria. Pectineal myotomy, intertrochanteric osteotomy, and dorsal acetabular rim arthroplasty are examples of surgeries that were historically proposed, but are not widely recommended currently.^{94,104,105} Surgeries that are still recommended and commonly performed for CHD include: juvenile pubic symphysiodesis (JPS), double pelvic osteotomy (DPO), triple pelvic osteotomy (TPO), femoral head and neck excision (FHNE), and various versions of total hip replacement (THR).^{103,106-109} None of these surgeries perfectly fit the criteria as the ideal surgery for CHD; they each have their indications and limitations and will be discussed below.

Juvenile Pubic Symphysiodesis

The JPS procedure is a minimally invasive technique in which electrosurgery is used to induce thermal injury to the pubic symphysis resulting in premature closure and preventing future lateral growth at the pubis. The resulting cessation of growth of the acetabulum ventrally causes ventroversion of the acetabulum as the pelvis continues to grow dorsally from the triradiate physis.⁷⁸ In a controlled, prospective study, the technique has been shown to have excellent results in puppies with a positive Ortolani sign and DI score 0.4 to 0.6, fair to good results with DI scores of 0.6 to 0.75, and poor results in dogs with DI scores over 0.75. However, in all groups, JPS decreased the severity of coxofemoral OA compared to untreated dogs.³⁶

There are numerous advantages to the JPS technique. It can be performed with minimal equipment cost and expertise since there are no orthopedic implants required, the procedure is fairly noninvasive with only a small incision being required over the pubis, and incisional seroma is the only side effect reported.^{77,78,110} The major limitation of the JPS, and the reason it is not more widely applied as a technique is the fact that it must be performed at an early age. Significantly larger improvements in acetabular ventroversion are seen when JPS is performed at 15 weeks compared to 20 weeks of age.⁷⁸ In another study, JPS at 20 weeks failed to prevent OA at 2 years of age supporting the need for early JPS.¹⁰³ However, clinical signs of CHD are rarely manifested in puppies at 4 months of age. In order for the JPS to be more widely accepted and utilized, general practitioners will need to screen puppies for CHD with hip palpation and perhaps DI scoring to identify JPS candidates prior to clinical signs developing. If veterinarians become more adept at diagnosing puppies with CHD at 16

weeks of age, JPS can certainly play a major role in minimizing the clinical effects of CHD in dogs.

Femoral Head and Neck Excision

Femoral head and neck excision is an invasive surgical procedure in which the femoral head and neck are excised to remove the femoral component of the diseased CF joint and encourage the formation of a pseudoarthrosis instead.^{111,112} It is a salvage procedure performed in the end stage osteoarthritic hip after medical efforts for palliation have failed.⁹⁴ In general, this procedure achieves its goal of returning the patient to pain free ambulation.^{111,113} It might be said that the motto of the FHNE is: “It’s better to have half of a coxofemoral joint that is painless, than a painful intact coxofemoral joint.” In a long-term retrospective study of FHNE, almost all owners were satisfied with the clinical outcomes in their dogs, and few dogs had residual lameness or pain.¹¹⁴

However, there are some significant shortcomings of this technique. The same study found that FHNE resulted in some undesired outcomes. Operated legs were functionally shortened as the greater trochanter was translocated more dorsally by the pseudoarthrosis than prior to surgery, atrophy was a common finding even 8 years post operation, and jumping and climbing stairs was difficult, especially in larger dogs.¹¹⁴ Similar findings were found in an experimental study in which FHNE was performed on dogs with normal CF joints. Operated limbs were shorter, the CF joint lost range of motion, decreased weight bearing was seen on force plate analysis, and muscle atrophy was seen even at the end of the study 16 weeks after surgery.¹¹² It has often been noted that large breed dogs (greater than 14 or 17 kg) have a poorer functional outcome than

their smaller counterparts.^{94,113-115} Efforts to overcome these poor surgical results by using muscle slings and novel excision methods have not shown any benefit.^{112,113} Postoperative pain management has not been shown to improve outcomes either.¹¹⁵ Though there is not great evidence for it in the veterinary literature yet, physiotherapy is thought to be a key determinant in postoperative success with FHNE.¹¹⁶

In summary, FHNE is a commonly performed surgical technique for coxofemoral OA secondary to CHD. It has the distinct advantages of being performed by both veterinary surgeons and general practitioners with surgical experience, does not require many specialized surgical instruments, and can alleviate OA pain in patients.¹¹¹ However, FHNE is an invasive technique that is not beneficial until the late stages of OA, causes anatomic disruption of the CF joint, and results in suboptimal function for the patient, especially larger ones.^{94,111,112,114} These findings have led to the development of total joint replacement as a method of treatment for end stage OA with CHD.

Total Hip Replacement

Total hip replacement is an invasive surgical procedure in which the entire coxofemoral joint is typically replaced by two prostheses, an acetabular component and a femoral component. Much like the FHNE, this surgery is a salvage procedure reserved for patients with severe OA in which nonsurgical management has failed.^{18,117} There has been a recent expansion in available implant sizes such that a dog as small as 3 kilograms can have a total hip replacement.¹¹⁸ The differences between THR and FHNE become readily apparent when comparing surgical technique, potential complications, and potential outcomes. Total hip replacement cannot be performed prior to 10 months of

age due to the potential for continued growth of the acetabulum and proximal femur.¹¹⁹ Total hip replacement is a demanding surgery that requires the skills of a surgeon experienced with the technique.¹²⁰ Several THR systems are now available with similarly reported success rates and separate technical advantages of each.^{118,121,122} However, the cost of THR is significantly more and its availability significantly less than FHNE. Yet, to many owners, the advantages of THR greatly outweigh its costs compared to FHNE. In a well controlled prospective study, dogs with THR implanted using bone cement were shown by force plate to overcome all lameness by 6 months after surgery.¹²³ A more modern system without cement was recently shown to have similar results by 3 months after surgery.¹⁰⁸ The THR is impressive in its ability to return dogs with coxofemoral OA to normal function. However, when complications occur (reported rates are 4 to 11%), they can be severe.^{124,125} Reported complications of THR include luxation, infection, fracture, aseptic loosening of the implants, fatal pulmonary thromboembolism, and sciatic neuropraxia.¹²⁴⁻¹³⁰ So, with the THR, the greater potential for full return to function comes at greater risk and much greater expense than that of the FHNE.

The Case for Pelvic Osteotomy

Because the JPS procedure must be performed by 5 months of age, and because THR cannot be performed until after 10 months of age and usually to treat end stage OA, an intermediate surgery to bridge these age limitations is necessary.^{78,119} Traditionally, the TPO procedure fills this role. The TPO was originally proposed as a treatment for dogs that are presented with lameness from CHD at 6 to 10 months of age. The goal of

the procedure is to rotate the opening of the acetabulum ventrally to improve the dorsal coverage of the femoral head and prevent subluxation secondary to hip joint laxity. This goal is achieved by performing three osteotomies of the pelvis, one each at the pubis, ischium, and ilium. The ilial osteotomy is stabilized by a bone plate and screws, and a hemicerclage wire. The ischial osteotomy is stabilized by a single hemicerclage wire.¹³¹⁻¹³³ The distinct advantages of the procedure are that, if done early enough, lifelong OA of the CF joint can be prevented, the procedure is performed while the puppy has great healing potential, and this surgery does not preclude future THR.^{133,134} Successful TPO has accomplished these goals well. An evaluation of clinically affected dogs with TPO documented a significant increase in hip congruity and decrease in hip laxity by CT examination.¹³⁵ In a prospective study of 15 dogs with CHD, TPO successfully improved weight bearing to almost normal levels by force plate analysis, resolved clinical lameness in 92% of dogs, and prevented progression of OA at 28 weeks after surgery.⁷⁶ Another study with 1 year follow up found that OA progressed, but to a much lesser degree than the unoperated hip, and dramatic improvements in weight bearing on force plate analysis.⁷⁵

However, the age of TPO patients seems to be a double-edge sword. While a young patient may have increased regenerative potential, soft bone and increased activity levels may predispose these patients to implant failures.^{132,134} Reported complications include pain, iliopsoas muscle impingement, incisional drainage, seroma, sciatic neuropraxia, dysuria, acetabular fractures, late osteosarcoma, inadequate reduction of ilial osteotomies, and implant failure.^{132,134,136-139} A report in 1993 found implant complications occurred in 50% of operated patients. All complications were managed

conservatively and resulted in 25% of patients having gait abnormalities 6 months postoperatively.¹⁴⁰ Another report from the same year at another institution found an implant loosening rate of 33%, but none of their patients required revision, and none had loss in acetabular ventroversion from loosening.¹⁴¹ More recently, a report of four dogs with complete implant failure following TPO documented two dogs that were successfully revised with a ventral plating technique, one dog with a poor final outcome, and a fourth dog that was euthanized after two failed revisions.¹⁴² These reports highlighted an obvious shortcoming of the TPO procedure and need for further evaluation of the technique.

Refinement of the Triple Pelvic Osteotomy Technique

Since the introduction of the TPO, there have been numerous publications to investigate the cause of implant loosening and attempts to refine the technique. The most cranial two screws were found to loosen most commonly.¹⁴³ Use of the ischial cerclage wire was found to decrease screw loosening in one study, but not in another.^{143,144} Bilateral, single procedure TPO has been found to be at increased risk.¹⁴⁵ Use of a twisted dynamic compression plate (DCP) to stabilize the ilial osteotomy and shallow penetration of the cranial screws into the sacrum were found to increase the risk of screw loosening.^{143,144} The authors recommended that the cranial screws be inserted maximally into the sacrum without entering the vertebral canal.¹⁴⁴ A later study, however, recommended that cancellous (instead of cortical) type screws be used and intentionally not engage the sacrum in an effort to prevent screw loosening.¹⁴⁶ Using self-tapping cortical screws instead of tapping screw holes by hand has also been found to decrease

the risk of screw loosening.¹⁴⁷ However, despite all these recommendations, only preemptive ventral plating in addition to the custom made TPO plate (canine pelvic osteotomy plate, CPOP, Slocum Enterprises, Eugene, OR) has completely eliminated the incidence of cranial ilial screw loosening.¹⁴⁵ Additionally, it has been proposed to radiograph TPO patients at 10 days after surgery and tighten loose screws at that time under fluoroscopic guidance. Yet, even with this technique, 25% of retightened screws were loose again at 60 days.¹⁴⁸

Additional studies have recommended further modifications of the technique. Graehler et al performed a controlled cadaveric study to evaluate the ilial osteotomy angle (compared to a line the perpendicular to the long axis of the ilium), axial rotation (20°, 30° or 45°), and the use of a twisted dynamic compression plate (DCP) or CPOP on acetabular ventroversion and pelvic collapse.¹⁴⁹ As recommended by Hosgood et al, Graehler's findings supported the use of the CPOP plate over the twisted DCP because the CPOP preserved the pelvic diameter better.¹³⁶ Also, angled ilial osteotomies (>0°) were found to prevent lateralization of the acetabulum, theoretically decreasing the forces creating implant loosening of the cranial screws.¹⁴⁹ A 20° osteotomy has been recommended because 30° was not significantly greater than 20°, and a 30° osteotomy may make implant placement in the caudal segment more difficult. As one might expect, increased axial rotation increased the ventroversion of the acetabular segment.¹⁴⁹

In order to determine the optimal axial rotation (plate size) to use for TPO, Dejardin et al conducted an anatomic study of normal and dysplastic canine coxofemoral joints.¹⁵⁰ They used a custom made plate with a hinge and goniometer to change the axial rotation of the TPO on each specimen. In dysplastic specimens, spontaneous

relocation of the femoral head back into the acetabulum occurred at an average of 17.2° of ventroversion.¹⁵⁰ In agreement with Graehler et al, increases in axial rotation continually increased acetabular coverage of the femoral head.¹⁴⁹ However, beyond 20° of ventroversion, acetabular coverage did not increase dramatically. Therefore, the authors recommended 20° of axial rotation as a maximum for the TPO since greater than that degree would theoretically increase the risk of delayed union and implant failure from the technique.¹⁵⁰ A retrospective study comparing clinical patients that had either a 20° or 30° CPOP supported this finding. The authors found no significant difference in percent coverage of the femoral head or difference in Norberg angles between the groups on recheck radiographs.¹⁵¹

In summary, to decrease complication rates, TPO should be performed unilaterally with a 20° ilial osteotomy, stabilized by a 20° CPOP.^{136,149,150} Screws in the cranial holes should either be cancellous screws that do not engage the sacrum, or self tapping cortical screws that engage as much of the sacrum as possible without entering the spinal canal.^{144,146,147} Whether or not ischial hemicerclage wire is beneficial is debatable.^{143,144} If screw loosening is seen at 10 days, fluoroscopic tightening can be beneficial in preventing loss of rotation.¹⁴⁸ Despite these recommendations, screw loosening of the most cranial two screws is still a common complication of TPO. Additionally, since CHD is most often a progressive disease that affects dogs bilaterally, successfully addressing both coxofemoral joints simultaneously would be in the patient's best interest.⁷³

Double Pelvic Osteotomy

With the complications of TPO in mind, the DPO was introduced in 2006 as an alternative to the TPO as currently performed.¹⁵² The DPO is performed similarly to the TPO in that the pubic and ilial osteotomies are made in the same fashion, and the ilial osteotomy is stabilized with a CPOP or similar bone plate. However, the ischial osteotomy is replaced with transection of the sacrotuberous ligament, or avoided altogether.^{106,153} Potential advantages of the DPO are that by leaving the ischium intact, the resulting pelvic construct is theoretically more stable, potentially resulting in less postoperative pain and fewer complications from implant loosening and secondary pelvic collapse.¹⁰⁶ It seems the claims of decreased complications rates may prove to be true. In a report on the results of 54 DPOs in 34 dogs, 3.5% of implants failed and 9.4% of plates had partial loss of reduction.¹⁰⁶ Overall, this 12.9% complication rate compares favorably to the TPO's best implant complication rate of 33%.¹⁴¹ An additional benefit to the DPO is that patients that required bilateral pelvic osteotomy had it in a single session without an increase in complication rate.¹⁰⁶ The DPO was also shown to significantly increase Norberg angles and percent coverage of the femoral head immediately postoperatively. These increases were maintained at 30 and 60 day follow-up radiographs.¹⁰⁶

Despite these promising clinical results, since the DPO is such a paradigm shift from the traditional TPO, previous research on the TPO technique may not directly translate to support the DPO technique. This thought is illustrated by the fact that 7.5% of DPOs result in ischial fracture, a complication that does not occur with TPO.¹⁰⁶ Haudiquet & Guillon realized this when they introduced the technique in 2006. In their

report, they compared acetabular areas of ventrodorsal radiographs of pelvis stabilized by TPOs of 20°, 25° and 30° to DPOs performed at 25°. Since the DPO relies on deformation of the pelvis caudal to the acetabulum to allow for ventroversion of the coxofemoral joint, their concern was that the DPO would not achieve the same degree of ventroversion with the same plate size as the TPO. They found that to be true.¹⁵² Based on their study, they recommended using a 25° plate to perform a DPO with the same ventroversion as a TPO with a 20° plate.¹⁵² These are the same recommendations made in Vezzoni's clinical report.¹⁰⁶

With only one peer reviewed publication on DPO, the arguments for DPO have little evidence thus far. The Haudiquet abstract gives a good general guideline to surgeons that an increased axial rotation is needed for the DPO compared to TPO.¹⁵² The Vezzoni report gives some good early proof of concept evidence that the DPO results in what appears to be clinically significant ventroversion of the acetabulum with a low complication rate thus far.¹⁰⁶ However, the study fails to include a positive or negative control group on which to compare results, and with 54 patients, the sample size is relatively small. So, there are questions about the DPO technique that still remain. For example, where does the deformation in the pelvis caudal to the acetabulum occur? Is a 5° increase in axial rotation enough to account for the loss of rotation from DPO compared to TPO in a three dimensional model of pelvic osteotomy? What is the true complication rate of DPO to TPO in a controlled cohort study? Does DPO decrease the progression of coxofemoral OA in dogs with CHD similarly to the TPO? Does DPO truly result in less postoperative pain for patients? If further research on DPO answers these questions sufficiently and proves itself to be a major improvement in these regards

over the TPO, then DPO has the potential to be a major advancement in the treatment of CHD in young dogs. The purpose of my thesis is to answer the first two of these questions as a step in that direction.

Chapter 2

Acetabular Ventroversion with Double Pelvic Osteotomy versus Triple Pelvic Osteotomy: A Cadaveric Study in Dogs

Introduction

The double pelvic osteotomy procedure is a modification of the triple pelvic osteotomy technique for the treatment of canine hip dysplasia.¹⁰⁶ Since the DPO alters the anatomy of the canine pelvis by torsion of the caudal segment of pelvis rather than rotation allowed by an osteotomy as with the TPO, questions about the region of torsion and its effect on surgical outcome are understandable.¹⁰⁶

The purpose of this study was to compare the acetabular ventroversion achieved after DPO using 3 different plate angles (20°, 25°, 30°) with that achieved by conventional 20° TPO. Secondly, pelvic bone angles were compared using 6 anatomic references pre- and postoperatively for each technique to identify the relative anatomic location of the hemipelvic torsion caused by DPO. Based on previous work by Haudiquet and Guillon,¹⁵⁴ our hypothesis was that 25° DPO would result in a degree of acetabular ventroversion most similar to 20° TPO. A secondary hypothesis was that ventroversion of the acetabular segment of the hemipelvis after DPO results from rotation of the pubic symphysis because an ischial osteotomy is not performed.

Materials and Methods

Large breed canine cadavers (n = 8) were obtained after euthanasia for reasons unrelated to this study. None of the dogs had a previous history of musculoskeletal

malformation, systemic disease, or trauma based on verbal history and physical examination.

Specimen Collection- The entire pelvis was dissected free by transecting between the 6th and 7th lumbar vertebrae (L7), amputating the tail caudal to the 4th caudal vertebra, and disarticulating the femora from the CF joints by incisions in the joint capsule, ligamentum teres, and supporting musculature. Soft tissues were removed from each specimen being careful to leave the lumbosacral and sacroiliac articulations, and both of the sacrotuberous ligaments intact and undisturbed. Care was taken to not damage the bone or any of the tissues particularly around the pubic symphysis and acetabulae. The articular cartilage and periarticular soft tissues of each CF joint were inspected for signs of osteoarthritis, malformation, or trauma. During dissection, each specimen was moistened repeatedly with isotonic saline (0.9% NaCl) solution. After dissection, the pelvises were wrapped in moist towels, double wrapped in plastic, and frozen at -20°C for up to 3 months.

Specimen Preparation- For the experiment, specimens were thawed in a room temperature water bath overnight. During each step in the procedure, a spray bottle with physiologic saline solution was used to keep the specimens moist. In each hemipelvis, bilateral holes were drilled from lateral to medial at one-third the distance from the dorsal most aspect to the ventral most aspect of the iliac crest. A commercially available aiming device (Synthes Vet, West Chester, PA) was used to ensure that the bone tunnels were drilled accurately from one iliac crest to the other. A ¼ inch threaded nylon rod was screwed by hand into both iliac crests. The dorsal spinous process of L7 was removed

with rongeurs to prevent impingement of the nylon rod. The rod was used to suspend the pelvis in a U-shaped acrylic custom jig.

Each specimen was securely mounted from the iliac crests cranial and dorsal to L7 and effectively outside the weight-bearing axis of the pelvis (Figure 2-1). The nylon rod did not contact the pelvis anywhere other than the tunnels in the iliac crests. A groove in the jig allowed the rod to be raised and lowered so that the pelvis could be mounted with the long axis of the ilium at 40° from horizontal, after which the rod was locked to the jig by two ¼ inch nylon washers and two ¼ inch nylon nuts on each side.




Figure 2-1. Photos from the craniolateral (A) and caudal (B) direction of a dissected pelvis and mounted in the custom acrylic jig before the first computed tomography scan.

Ventrodorsal and lateral radiographic projections of mounted specimens were used to confirm normal bony anatomy and conformation. The pelvis and jig were positioned in a computed tomography (CT) scanner (Picker PQ 6000, Philips Healthcare, Andover, MA) with the aid of crossed lasers to ensure repeatability in positioning between CT sessions. During the initial CT scan (subsequently referred to as Baseline),

initial slices were taken to be sure the pelvis was mounted level to the dorsal plane. Once this was confirmed, acrylic glass struts were securely fashioned with adhesive tape (Scotch® Magic™ tape, 3M, St. Paul, MN) to the jig to support the rod before the nuts were tightened. These struts ensured that the pelvis was mounted identically between CT sessions. Two nylon nuts were tightened against each other and positioned against the jig at a fixed location on the nylon rod so that the medial to lateral position of the pelvis and jig did not vary between CT sessions.

Contiguous 1 mm transverse CT slices (80-120 kVp, 160 mA) were taken of the entire pelvis from the most cranial aspect of the iliac crest to the most caudal aspect of the ischium with the gantry in the vertical position as described by Wang et al.¹⁵⁵ After baseline CT scan, the first specimen had DPO with a 20° plate (20°DPO) performed on the right hemipelvis. A coin toss was used to select which side was operated first. Each successive pelvis had the procedure performed on the opposite side so that DPO was performed on the right side of 4 specimens and the left of 4 specimens.

For DPO, a pubic osteotomy that excised the entirety of the iliopubic eminence was performed using an oscillating sagittal saw. The sacrotuberous ligament was then removed only from the operated side. Finally, iliac osteotomy was performed as described for TPO.¹⁵⁶ The dorsoventral iliac osteotomy was oriented 20° in the caudal direction from a line perpendicular to the long axis of the ilium by use of a custom made jig.¹⁴⁹ A 20° plate (Locking Triple Pelvic Osteotomy Plate, New Generation Devices, Glen Rock, NJ) was fastened with three 3.5 mm cortical bone screws to the caudal segment with the osteotomy in contact with the step in the plate and the ventral aspect of the plate level with the ventral margin of the ilium. The cranial aspect of the plate was

then fastened to the cranial ilium again at the ventral aspect with three 3.5 mm cortical bone screws. Fixed 90° angle drill guides (3.5 mm Locking Drill Guides, New Generation Devices) specifically designed for use with the plate were used to drill all screw holes. All screws engaged both cortices of the ilium without penetrating the sacrum. The same 6 plates (one left 20°, one right 20°, one left 25°, one right 25°, one left 30°, and one right 30°) were used throughout the experiment, so that all 4 left 20° DPO and left 20° TPO used the same left 20° plate, all 4 right 30° DPO used the same right 30° plate, etc. The pelvis was repositioned in the jig on the previously secured struts with the double nut against the jig to ensure its position in the jig was identical to the first CT (Baseline). Lasers were used to reposition the jig in the CT. A second CT scan (subsequently referred to as 20°DPO) was performed identically to the first.

To mimic a DPO of 25°, the pelvis was removed from the jig. The 20° plate was carefully removed and replaced with a 25° plate (New Generation Devices) that accommodated screws in the same position. Pelvis positioning was performed again for a third CT scan (25° DPO). A fourth CT (30° DPO) was performed with a 30° plate (New Generation Devices) to mimic a DPO of 30°. Finally, to mimic a TPO of 20°, the 30° plate was removed, an osteotomy of the ischium into the lateral limit of the obturator foramen was made in the sagittal plane using an oscillating saw as described.¹⁵⁷ Bone tunnels were drilled on either side of the osteotomy so that a loop of #1 braided suture (Polysorb, Covidien, Mansfield, MA) could be placed to mimic the hemicerclage wire typically used in clinical practice. The pelvis was positioned and imaged by CT scan (20°TPO).

Measurements- Six measurements were made from each CT study (Figure 2-2). The iliac crest angle (IICr) was measured on the most caudal image of the iliac crest that did not include any portion of the sacroiliac articulation. The pre-acetabular angle (PreAce) was measured from the most caudal image cranial to the acetabulum that did not include any of the widening of the iliac body as it transitions into acetabular bone. The acetabular angle (AA) was measured from the first image cranial to the fovea capitis that included the ventral acetabular rim. The post-acetabular angle (PostAce) was the first image caudal to the acetabulum, but otherwise similar to the PreAce. Cranial (CrIs) and caudal ischial (CdIs) angles were measured from the most cranial and caudal images, respectively, that included the symphysis pubis.

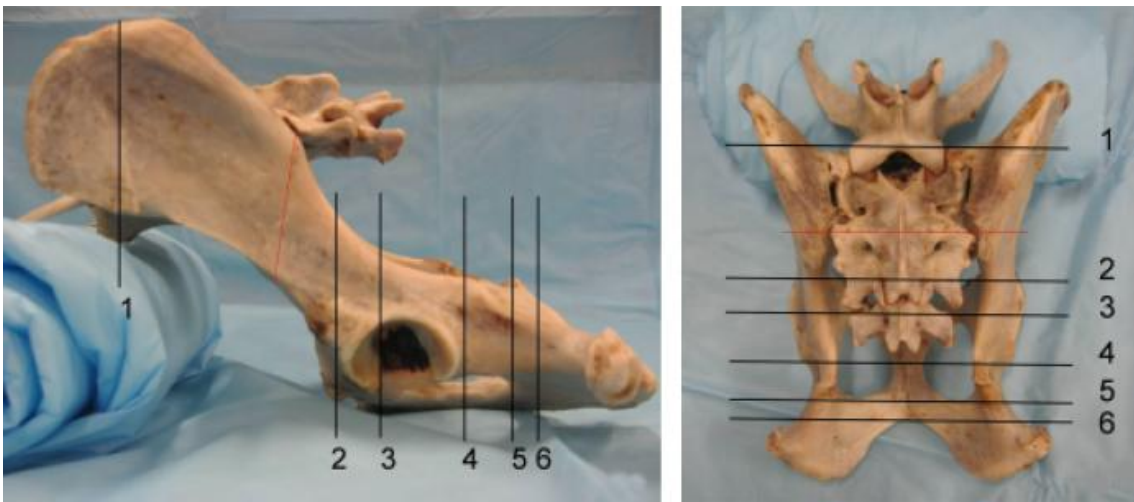

Figure 2-2. Lateral (A) and dorsal (B) views of a canine pelvis and sacrum with black lines to represent the computed tomography slices for the angles. 1) iliac crest 2) pre acetabular 3) acetabular angle 4) post acetabular 5) cranial ischial 6) caudal ischial. A dashed red line indicates the location and direction of the iliac osteotomy.

All measurements were made in relation to a midline drawn from the AA image and defined as a line that bisected the symphysis pubis, vertebral canal, and dorsal spinous process. The software used to make the angle measurements (reViewMD, v2.0,

Digisoft, LLC 2002, Philadelphia, PA), allowed for the same midline to be transferred onto the other CT images so that the exact midline representing the median plane was used to calculate the other 5 angles for each CT study. The AA was drawn as described in an anatomic study of the canine pelvis by Wang et al., except that instead of the AA being a single measurement combining the angles from both acetabulae, the value was calculated as an angle from midline for each acetabulum (left and right; Figure 2-3).¹⁵⁵ The other 5 angles were created by drawing a line representing the medial cortex of the ilium to intersect the midline.

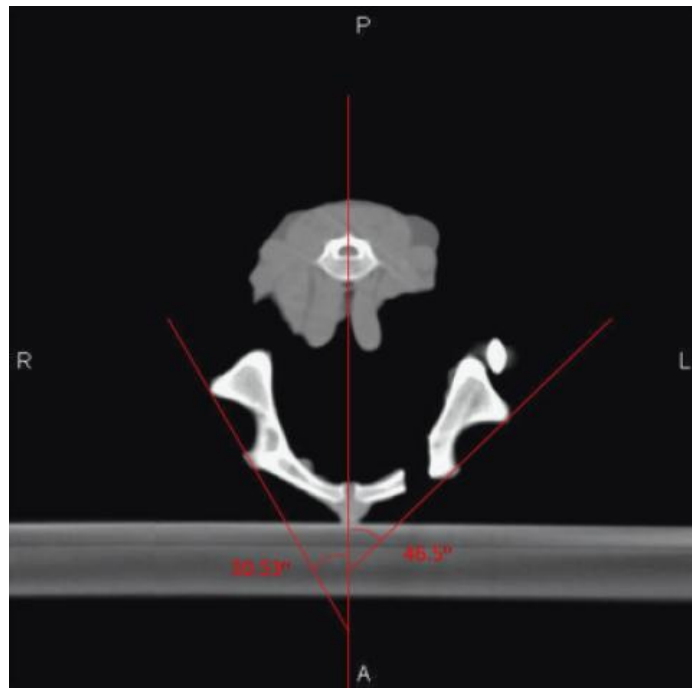


Figure 2-3. Computed tomographic image illustrating a line drawn to represent the midline of the pelvis and lines drawn to represent the acetabular angles for each hemipelvis

For the 20° TPO, CrIs and CdIs angles were measured using a line along the ischial cortex still contacting the symphysis pubis. Lines that were drawn towards the midline in a dorsoventral direction were designated as positive angles whereas those directed away were considered negative. For change in ventroversion measurements

between CT studies, an increase in ventroversion was deemed to be a positive change. All 6 measurements were made bilaterally (operated and unoperated hemipelvis) for each CT study. This measurement protocol was repeated in each of the 8 pelvises.

Statistical Analysis- To evaluate the agreement between angle measurements for TPO and the 3 DPO procedures, the concordance coefficient, ρ_c , was used.^{158,159} The concordance coefficient measures the correlation between 2 measurements (e.g., angles) from the same sample (e.g., dog) by measuring the variation departing from perfect agreement (which is a 45° line through the origin, known as the concordance line). The mathematical formula for ρ_c is complex, but in its essence is a Pearson's correlation multiplied by a bias correction factor. Interpretation of the coefficient is similar to that of Pearson's correlation: values of 1 imply perfect agreement, whereas values of -1 imply perfect reverse agreement (i.e., disagreement). Estimates of the concordance coefficient and associated 95% confidence intervals (95% CI) were computed using a custom macro written for use with software (SAS software, Version 9.2, SAS Institute Inc., Cary, NC).

Results

Cadaver weights ranged from 13.2 to 19.2 kg (mean, 16 kg). Dogs were aged 6 - 8 months of age (mean, 6.5 months); and there were 2 intact males and 6 intact females.

Acetabular angle measurements (mean \pm SD) for Baseline, 20° DPO, 25° DPO, 30° DPO, and 20° TPO were 32.89 ± 2.23 , 47.39 ± 4.39 , 51.43 ± 5.06 , 54.75 ± 4.38 , and 50.20 ± 5.76 respectively. Figure 2-4 illustrates the AA for both operated and unoperated hemipelvises. Tables 2-2 and 2-3 are calculated values from Table 2-1 and enumerate the change in angulation for that technique compared to the same unoperated hemipelvis

(Baseline) and the change in angulation compared with the previous step in the experimental procedure (for example, 25° DPO to 30° DPO) respectively. In particular, 20° DPO, 25° DPO, 30° DPO, and 20° TPO increased AA ventroversion by 14.51 ± 2.83 , 18.55 ± 3.05 , 21.86 ± 2.56 , and 17.32 ± 3.70 respectively. Changes in AA from the previous technique were 14.51 ± 2.83 , 4.04 ± 2.19 , 3.32 ± 1.49 , and -4.55 ± 2.71 for Baseline to 20° DPO, 20° DPO to 25° DPO, 25° DPO to 30° DPO, and 30° DPO to 20° TPO respectively. The ventroversion obtained from 25° DPO compared to Baseline at PreAce, AA, PostAce, CrIs, and CdIs were 18.80 ± 4.86 , 18.55 ± 3.05 , 17.32 ± 5.62 , 16.43 ± 5.06 , and 18.17 ± 5.90 respectively. Concordance correlation results are summarized in Figure 2-5. Compared to 20° TPO, concordance correlation coefficient (95% CI) for Baseline, 20° DPO, 25° DPO, and 30° DPO were 0.027 (-0.059 to 0.113), 0.721 (0.283 to 0.910), 0.902 (0.636 to 0.977), and 0.593 (0.174 to 0.830).

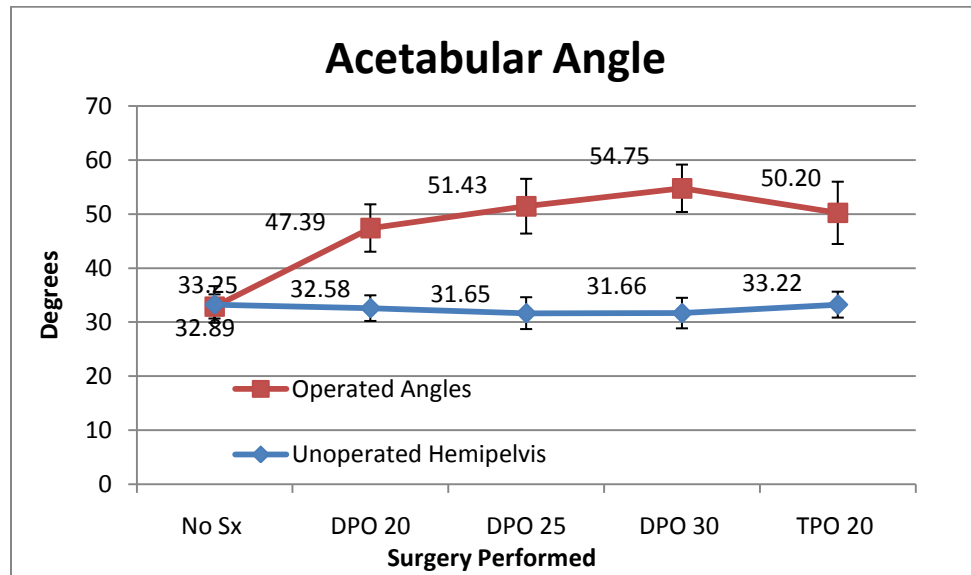


Figure 2-4. Line graph comparing the average acetabular angle (AA) values of the unoperated hemipelvis to Triple Pelvic Osteotomy at 20°, and Double Pelvic Osteotomy performed at 20°, 25°, and 30° of ventroversion.

Table 2-1. Mean \pm SD Anatomic Angle Measurements for Baseline and after Double Pelvic Osteotomy (DPO at 20°, 25°, 30°) and Triple Pelvic Osteotomy (20° TPO)

Angles	20° DPO	25° DPO	30° DPO	20° TPO
IICr	-4.33 \pm 2.99	-5.12 \pm 3.56	-6.60 \pm 3.27	-2.79 \pm 5.63
PreAce	15.56 \pm 4.35	18.80 \pm 4.86	23.99 \pm 5.79	17.06 \pm 7.26
AA	14.51 \pm 2.83	18.55 \pm 3.05	21.86 \pm 2.56	17.32 \pm 3.70
PostAce	12.92 \pm 4.78	17.32 \pm 5.62	21.83 \pm 5.05	17.96 \pm 6.27
CrIs	12.64 \pm 4.87	16.43 \pm 5.06	19.44 \pm 5.26	9.46 \pm 3.41
CdIs	14.64 \pm 5.27	18.17 \pm 5.90	23.05 \pm 5.13	7.87 \pm 2.98

IICr = Iliac crest angle; PreAce = pre acetabular angle; AA = acetabular angle; PostAce = postacetabular angle; CrIs = cranial ischial angle; CdIs = caudal ischial angle

Table 2-2. Mean \pm SD Change in Anatomic Angle Measurements from Baseline after Double Pelvic Osteotomy (DPO at 20°, 25°, 30°) and Triple Pelvic Osteotomy (TPO at 20°). Angle Abbreviation Key provided with Table 2-1. A Positive Angle Change Represents an Increase in Ventroversion

Angles	Baseline	20° DPO	25° DPO	30° DPO	20° TPO
IICr	-2.78 \pm 4.73	-7.11 \pm 4.44	-7.90 \pm 6.14	-9.38 \pm 5.78	-5.57 \pm 7.66
PreAce	0.84 \pm 1.14	16.40 \pm 5.09	19.64 \pm 5.35	24.83 \pm 6.50	17.89 \pm 7.73
AA	32.89 \pm 2.23	47.39 \pm 4.39	51.43 \pm 5.06	54.75 \pm 4.38	50.20 \pm 5.76
PostAce	-1.20 \pm 2.46	11.72 \pm 5.56	16.12 \pm 6.43	20.63 \pm 6.19	16.77 \pm 7.61
CrIs	61.06 \pm 4.75	73.70 \pm 7.07	77.48 \pm 8.72	80.50 \pm 8.19	70.52 \pm 6.35
CdIs	60.35 \pm 5.07	74.99 \pm 6.20	78.52 \pm 8.55	83.40 \pm 7.24	68.22 \pm 4.54

Table 2-3. Mean \pm SD Change in Anatomic Angle Measurements between Successive Osteotomy Techniques Angle Abbreviation Key provided with Table 2-1. A Positive Angle Change Represents an Increase in Ventroversion

	Baseline to 20° DPO	20° DPO to 25° DPO	25° DPO to 30° DPO	30° DPO to 20° TPO
ILCr	-4.33 \pm 2.99	-0.79 \pm 2.72	-1.48 \pm 2.51	3.81 \pm 3.70
PreAce	15.56 \pm 4.35	3.24 \pm 4.18	5.19 \pm 2.89	-6.93 \pm 3.90
AA	14.51 \pm 2.83	4.04 \pm 2.19	3.32 \pm 1.49	-4.55 \pm 2.71
PostAce	12.92 \pm 4.78	4.40 \pm 2.24	4.51 \pm 1.52	-3.86 \pm 2.23
Crls	12.64 \pm 4.87	3.78 \pm 2.89	3.01 \pm 2.29	-9.98 \pm 7.10
Cdls	14.64 \pm 5.27	3.53 \pm 2.93	4.88 \pm 2.56	-15.80 \pm 7.05

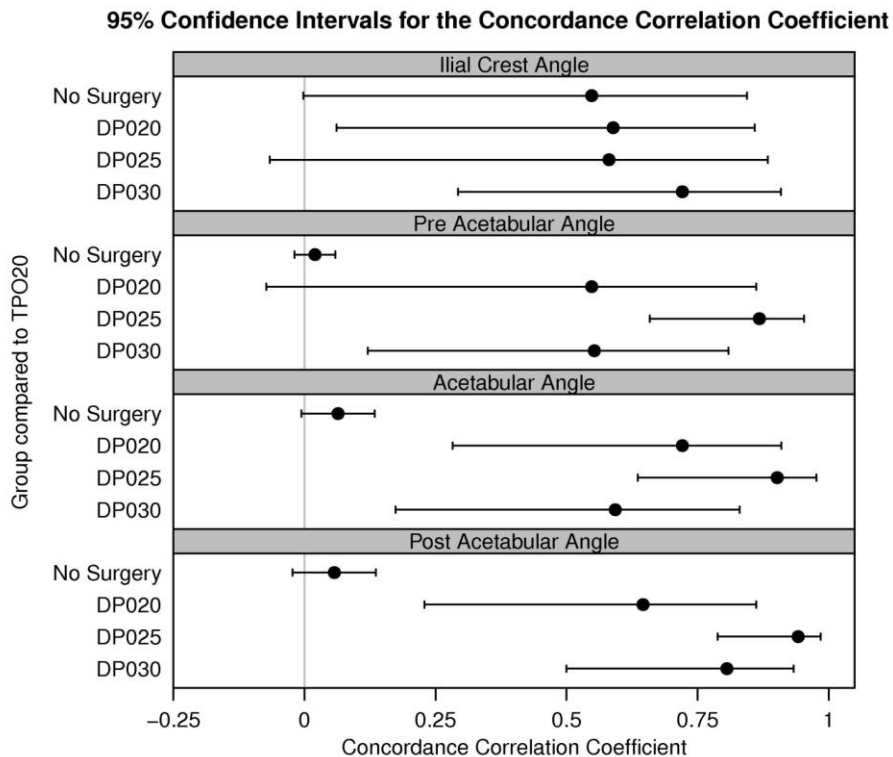


Figure 2-5. 95% Confidence intervals for the concordance correlation coefficient comparing triple pelvic osteotomy performed at 20° (TPO20) to control (No Surgery) or double pelvic osteotomy performed at 20°, 25°, or 30° (DPO20, DPO25, DPO30).

Discussion

Based on the *in vitro* work of DeJardin et al, the maximum recommended ventroversion of the acetabular component for TPO is 20°, as measured by applying a custom made plate that was able to adjust its degree of angulation. Results of that study discouraged the use of more angulated plates for TPO because of the perceived risk of increased morbidity with increased plate angle size.¹⁵⁰ This recommendation has been given more support by a clinical study by Tomlinson and Cook who reported no difference in Norberg angles and percent coverage of the femoral head immediately postoperatively and at subsequent rechecks between dogs that had 20° TPO compared with those that had 30° TPO.¹⁵¹

Because of this, we used 20° TPO as the standard technique to replicate with different angled DPO. We found CT to be an accurate and repeatable tool for measurement of acetabular angles to quantify the acetabular ventroversion resulting from each procedure. We found that 25° DPO compared most similarly to 20° TPO with a highly favorable concordance correlation ($\rho_c = 0.90$). This result directly correlates to the findings of previous radiographic and clinical studies comparing TPO and DPO.^{154,160} We found that 25° DPO resulted in a mean ventroversion angle 1.23° greater than that of the 20° TPO (51.43° versus 50.20°). Concordance correlation ($\rho_c = 0.72$) supports 20° DPO as the second most likely procedure to mimic the results of 20° TPO.

The choice of the concordance coefficient for evaluating the agreement between the procedures was critical, as many commonly used statistical measures of agreement (e.g., Pearson's correlation, Spearman's correlation, paired t-test, or least-squares analysis of slope=1 and intercept=0) have shortcomings that, if used in our current

settings, would overstate the *extent* of agreement between procedures, as well as the *nature* of the agreement.¹⁵⁹ For example, Pearson's or Spearman's correlation would indicate perfect agreement even though each pair of angles differed by 10°, which is clearly not an acceptable property in our setting. The concordance coefficient doesn't have this flaw. Lin gives graphical illustrations of the shortcomings for other methods used in scenarios similar to this current study.¹⁵⁹

Plastic deformation of the pelvis caused by DPO is a source of potential error in our results. Because TPO requires an ischial osteotomy and DPO does not, to perform the same technique on the same specimens, TPO had to be performed last. Because DPO relies on deformation of the hemipelvis caudal to the osteotomy to achieve ventroversion, and our experimental technique involved DPO of 20°, 25°, and 30° before TPO, it is likely that the acetabular segment was plastically deformed to some degree before TPO. If plastic deformation occurred in the iliac body cranial to the acetabulum or in the acetabulum itself, the deformation would have affected our results by artificially increasing the observed AA by 20° TPO.

In looking at the change in ventroversion from PreAce, AA, and PostAce for 20° TPO, the values were 17.06, 17.32, and 17.96 respectively. This 0.9° increase in ventroversion between the cranial measurement of PreAce to the more caudal measurement of PostAce suggests that there was potentially 0.9° of plastic deformation of the acetabular segment itself. If this assumption is true, the corrected AA measurement for 20° TPO would be 49.30°. Compared with 47.39° for 20° DPO, and 51.43° for 25° DPO, we would still recommend 25° DPO rather than 20° DPO. Given the option of over rotating the acetabulum by 2.13° to increase coverage of the femoral

head versus under rotation of 1.91° , seemingly over rotation would be preferable to increase acetabular contact area, preventing CF subluxation and secondary osteoarthritis. DeJardin et al. found increases in articular contact area with acetabular ventroversion of up to 30° , but warned of the potential for increased morbidity after the significant initial benefit of the 20° plate for TPO.¹⁵⁰ Use of a 20° plate for DPO results in acetabular ventroversion, but 1.91° lower than 20° TPO on average. This acetabular under rotation may still be clinically efficacious for prevention of CF subluxation in some dogs, but results in a ventroversion much closer to the cutoff ($17.2^\circ \pm 1.3$) ventroversion angle to increase articular contact area as recommended by DeJardin et al.¹⁵⁰ Therefore, based on our results a 25° plate for DPO would be preferable.

In evaluating the anatomic measurements of the ilium and ischium in different CT slices with DPO, there is evidence that supports our hypothesis of acetabular ventroversion mostly occurring because of rotation or flattening at the pubic symphysis (Figure 6). In looking at the increase in ventroversion from baseline (Table 2), the average change in ventroversion between each portion of the anatomy is similar (18.80, 18.55, 17.32, and 16.43 moving from cranial (PreAce) to caudal (CrIs) for the 25° DPO, for example) with a gradual 2.37° decrease in ventroversion between PreAce and CrIs. If ventroversion occurred solely because of torsion within the iliac body and acetabulum, one would expect a dramatic change in measured ventroversion over the length of the ilium and acetabulum. In fact, ventroversion occurred almost as much in the ischium as it did more cranially. The gradual slight decrease in ventroversion between measurement points moving from a cranial point (PreAce) to a caudal point (CrIs; 2.37° for a 25° plate) illustrates iliac torsion as a much smaller component of the ventroversion created

by the DPO technique, and perhaps represents 12% (2.37/18.8) of the overall ventroversion (18.8°). However, most (88%) ventroversion appears to occur at the level of the symphysis pubis. Both of the ischial angles show dramatic and similar degrees of ventroversion with each of the DPO techniques. CrIs angles before (baseline) and after DPO increase by a mean of 12.64 ± 4.87 , 16.43 ± 5.06 , and 19.44 ± 5.26 , and the CdIs angles by 14.64 ± 5.27 , 18.17 ± 5.90 , and 23.05 ± 5.13 for 20° DPO, 25° DPO, and 30° DPO, respectively. The unoperated hemipelvis' CrIs and CdIs showed no significant change in angles compared with baseline (data not shown) resulting in a measurable rotation at the pubic symphysis.

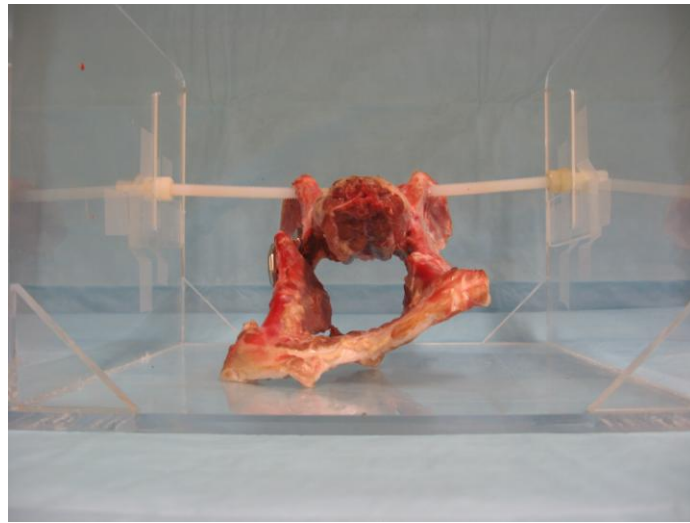


Figure 2-6. Photo from the caudal direction of a mounted specimen after having a double pelvic osteotomy of 30°. Note that acetabular ventroversion is achieved secondary to rotation of the symphysis pubis.

By comparison, TPO increased mean ventroversion of PreAce, AA, and PostAce 17.06, 17.32, and 17.96°, respectively. These very similar values illustrate the way that TPO causes ventroversion of the acetabulum by ventroversion of the entire segment as a

single unit, causing dorsal wedging of the ischial osteotomy. As mentioned earlier, we attribute the 0.9° difference to plastic deformation secondary to torsion induced by the previous DPO technique.

When evaluating the numerical data for acetabular ventroversion angles, it may be surprising that a 20° plate did not increase acetabular ventroversion by 20° in either DPO or TPO, and each 5° increase in plate size did not increase ventroversion by 5° either. This trend can be explained by the fact that the long axis of the canine hemipelvis is oriented at 40° from the frontal plane. When an iliac osteotomy is made at an angle other than 40°, rotation about the osteotomy results in rotation in the frontal plane as well as the transverse plane. Graehler et al recommended a 20° iliac osteotomy as a compromise between minimizing acetabular lateralization and preservation of sufficient bone stock in the acetabular segment for the placement of screws for plate fixation.¹⁴⁹ We used this recommendation in our study design. To minimize the variation of acetabular ventroversion by variation in iliac osteotomy angle, a custom Plexiglas cutting jig was used to make all iliac osteotomies in our study.

Our study was designed to mimic the clinical technique for DPO and TPO in an effort to make this study as clinically applicable as possible; however, there are several limitations to consider in the analysis of these results. The pelvis we used were from dogs with normal hip conformation, did not include the femoral portion of the CF joint, and did not evaluate the techniques' ability to prevent dorsolateral subluxation of the CF joint. Abnormal conformation in dogs with CHD may alter the anatomic alterations secondary to the DPO technique. We did not examine each technique's ability to prevent dorsolateral subluxation, perhaps a better functional measure of the techniques' clinical

applicability. We cannot comment on the temporal functional stability of the DPO modified pelvis. We believe that the DPO initially causes elastic deformation of the hemipelvis thus avoiding the need for ischial osteotomy. Further studies are needed to examine the ability of the DPO technique to decrease postoperative implant related complications or patient pain.

Summarily, DPO performed with a 25° plate results in an acetabular ventroversion angle most similar to TPO performed at the recommended 20°. Because DPO is a technique that has been adopted by some surgeons in an effort to decrease implant-related complications and patient morbidity, these recommendations may guide a surgeon in the selection of a plate that may improve the clinical outcomes of the DPO technique.

Chapter 3

Retrospective Comparison of Complication Rates between Double Pelvic Osteotomy and Triple Pelvic Osteotomy at the University of Missouri

Introduction

The purported advantages of the DPO over the TPO include increased biomechanical stability of the resulting hemipelvis construct, decreased implant-related complication rates, increased patient postoperative comfort, and the ability to perform pelvic osteotomy bilaterally without increased risk of complications. A study of clinical patients is required to best evaluate these proposed advantages in patients.

The Orthopedic Service at the University of Missouri Veterinary Medical Teaching Hospital (MU-VMTH) has been performing DPO on clinical patients requiring pelvic osteotomy for CHD since August of 2008. Prior to this time, TPO was the sole procedure performed. This shift in surgical paradigm provides an opportunity to study the two techniques side by side without case selection bias. Such a study was conducted and is summarized in this chapter. The purpose of this study was to compare the clinical complication rates and outcomes of both procedures in an effort to discover clinical evidence in support of or against the claim of improved clinical outcomes of DPO over TPO.

Materials and Methods

The electronic medical records database at the MU-VMTH was searched for cases that received either a DPO or TPO from January 1, 2006 to May 1, 2011. In order to be included in the study, patients had to have an osteotomy procedure performed for CHD,

and complete medical records including radiographs. Dogs that had staged bilateral procedures were counted as two separate cases of pelvic osteotomy, and data from each surgery was tabulated separately. Bilateral single session surgery would be recorded as a single case. Revision surgeries for major complications from DPO or TPO were recorded, but not included in analysis. Signalment and physical examination information including age at the time of surgery, gender, breed, and neuter status was recorded. Surgical information gathered included side of surgery, surgeon experience (faculty versus resident), concurrent surgeries performed, plate ventroversion angle, screw type (cortical versus cancellous), whether the surgery was the first or second osteotomy procedure for the patient, sacrotuberous ligament transaction for DPO, use of an ischial wire for TPO, and whether any intraoperative complications occurred. The medical records were also examined for follow up information about any complications that may have been discovered at subsequent rechecks, and recheck times were recorded as well. Complications were considered major if additional surgery was required or resulted in long-term detriment to the patient. A complication was minor if the complication could be treated medically and was of no long-term consequence. Catastrophic complications resulted in amputation of the limb or death of the patient. Outcomes were extrapolated from the text of the medical records at the final recheck examination. If the patient seemed to be improved due to the surgical procedure, then the outcome was considered “good”. If the patient was not improved, or worse than prior to the procedure, then the outcome was considered “not good”. Cases without follow up were excluded from outcome analysis.

Postoperative radiographs were reviewed for any intraoperative complications that may have been omitted from surgery reports, including broken screws or drill bits, incomplete reduction of the osteotomy, malpositioned osteotomies, and fractures. Recheck radiographs were reviewed for complications at follow up including, loss of reduction, implant loosening or failure, osteomyelitis, and fracture.

Complication rates between the two procedures were compared and potential contributing factors analyzed in an effort to identify confounding factors that may affect accurate comparison between the two techniques. Due to the low numbers of cases identified, only descriptive statistics (and not inferential statistics) were performed when applicable.

Results

From January 2006 to August 2008, twenty-two cases of TPO were identified. Fifteen had complete medical records and fit the inclusion criteria for this study. Since August 2008, fourteen DPOs had been performed and fit the inclusion criteria for this study. Descriptive data of individual cases of TPO and DPO are outlined in Tables 3-1 and 3-2, respectively. Eight of the TPOs were performed on the right, seven on the left. Nine of the DPOs were performed on the right, five on the left. Based on medical record review, a faculty member performed 26.7% of the TPOs and 64% of the DPOs. All of the DPOs performed by a resident were directly supervised by a faculty surgeon; 4 of the TPOs were performed by unsupervised residents.

Ages for the TPO and DPO patients were 8.3 (± 2.9) and 8.7 (± 2.09) months (\pm SD) respectively (Fig. 3-1). There were 9 castrated males, 6 spayed females, and no

Table 3-1. Descriptive Data for Clinical Patients receiving a Triple Pelvic Osteotomy (TPO)

TPO #	Surgeon (F/R)	Age (months)	Weight (kg)	Sex	Breed	Plate type (degrees)	1st, 2 nd , vs. Bilateral	Intraoperative complications	Follow up time (months)	Complications at recheck	Outcome
1	R	6	25.3	FS	Lab	20	1st	No	6	cr screw loosening	Good
2	F	7	25	FS	Lab	30	2nd	No	5	persistant pain in hip	Not good
3	R	6	29	MC	Golden	20	1st	No	6	ischial tuberosity fracture	Good
4	R	7	29	MC	Golden	20	2nd	cr osteotomy	5	implant failure	Not known
5	F	5	32	MC	Mixed breed	20	1st	cr osteotomy	18	No	Good
6	F	10	33	MC	Lab	20	1st	No	1	cr screw loosening	Good
7	R	7	25	FS	Am Staff terrier	20	1st	No	7	No	Good
8	R	8	24.5	MC	G. Shep	20	1st	No	30	No	Good
9	R	5	16.5	MC	Lab	20	1st	cr osteotomy	0	broken cerclage, cr screw loosening	Good
10	R	8	27	FS	Am Staff terrier	20	2nd	No	6	No	Good
11	R	10	30	MC	Aust cattle dog	20	1st	cr osteotomy	1	broken cerclage	Good
12	R	16	38.5	MC	Lab	30	1st	No	2	broken cerclage	Good
13	F	12	43.5	MC	Lab	30	1st	No	0	NA	Not known
14	R	8	21	FS	Border collie	30	1st	No	5	No	Good
15	R	9	21	FS	Border collie	20	2nd	cr osteotomy	4	implant failure	Good
Average		8.3	28.0						6.4		
SD		2.9	6.9						7.9		

F= faculty surgeon; R= resident surgeon; ST= sacrotuberous ligament; MC= castrated male; FS= spayed female; Lab= Labrador retriever; Golden= Golden retriever; Am Staff terrier= American Staffordshire terrier, G. Shep= German Shepherd dog; Aust cattle dog= Australian cattle dog; cr= cranial

Table 3-2. Descriptive Data for Clinical Patients receiving a Double Pelvic Ostetotomy (DPO)

DPO #	Surgeon (F/R)	Age (months)	Weight (kg)	Sex	Breed	Plate Angle (degrees)	ST transection	1st, 2 nd , vs. Bilateral	Intraoperative complications	Follow up time (months)	Complicatons at recheck	Outcome
1	R	11	70	MC	St. Bernard	20, double	ST transection	1st	No	29	Developed clinical OA	Not good
2	F	8	27.5	MC	Am bulldog	20	ST transection	1st	poor rotation	2.5	No	Good
3	F	8	35	MC	Mixed breed	not known	ST transection	1st	No	1.5	cd screw loosening	Good
4	R	9	27.8	MC	Am bulldog	20	ST transection	2nd	No	6	cr screw loosening	Good
5	F	11	27	FS	G. Shep	20	ST transection	1st	No	0	NA	Not known
6	F	10	39.6	FS	Lab	30	ST transection	1st	No	5	incisional dehiscence	Good
7	F	11	39.2	FS	Lab	30	ST transection	2nd	No	4	neuropraxia	Good
8	R	7	32.5	MC	Golden	30	ST transection	1st	No	1.5	No	Good
9	F	11	26.9	MC	Mixed breed	30	ST transection	1st	No	2	No	Good
10	R	6	23	MI	G. Shep	20	No	1st	No	1.25	Neuropraxia, continued laxity	Not good
11	F	6	30	MC	Golden	30, double	No	1st	No	3.5	No	Good
12	F	7	39	MC	Golden	30, double	ST transection	2nd	cr osteotomy	2.5	No	Good
13	R	6	33.3	FI	Bernese mt	30, double	No	1st	No	6	No	Good
14	F	11	26.4	FI	Lab	30	No	1st	No	2.5	No	Good
Average		8.7	34.1							4.8		
SD		2.09	11.63							7.2		

F= faculty surgeon; R= resident surgeon; ST= sacrotuberous ligament; MC= castrated male; FS= spayed female; MI= sexually intact male; FI=sexually intact female; Am Bulldog= American bulldog; G. Shep= German Shepherd dog; Lab= Labrador retriever; Golden= Golden retriever; Bernese mt= Bernese mountain dog; double= additional 2.7 mm dynamic compression plate; cr= cranial; cd= caudal; OA= osteoarthritis

sexually intact animals in the TPO group, and 8 castrated males, 3 spayed females, 2 intact females, and one intact male in the DPO group. Breeds represented in the TPO group were Labrador retriever (6), Golden retriever (2), American Staffordshire terrier (2), Border collie (2), German shepherd dog (1), Australian cattle dog (1), and a single mixed breed dog. Labrador retriever (3), Golden retriever (3), German shepherd dog (2), mixed breed (2), American bulldog (2), and single cases of Bernese mountain dog and Saint Bernard represented the DPO group. On average, TPO patients weighed 28 ± 6.9 (kg \pm SD); DPO patients weighed 34.1 ± 11.6 (Fig. 3-1).

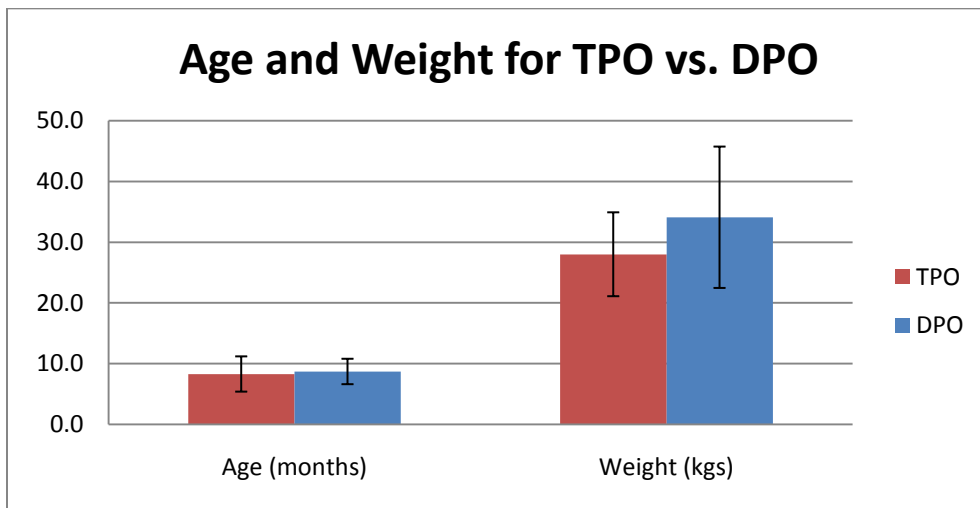


Figure 3-1. Bar graph comparing the ages and weights of patients having either a triple pelvic osteotomy (TPO) or double pelvic osteotomy (DPO).

From the medical records, DPOs and TPOs were performed with very similar technique across the multiple surgeons at the MU-VMTH. For example, all surgeries were performed with cortical screws and all TPOs had ischial hemicerclage wires, but no ilial hemicerclage wires placed. Eleven of the 15 TPOs were performed with 20° plates.

The other four were performed with a 30° plate. None of the TPOs or DPOs were performed bilaterally as a single procedure.

Illustrating the temporal transition between techniques at the MU-VMTH, the first five DPOs were performed with 20° plates as recommended for TPO. Eight of the last nine utilized a 30° plate, which is in line with recommendations for the DPO.¹⁵²

Surgeons transected the sacrotuberous ligament (ST) for the first 9 DPOs, and only one of the last 5. The current recommendations for DPO do not include ST transection.¹⁰⁶

When looking at whether the pelvic osteotomy technique was staged bilaterally, 26.7% of TPOs and 21.4% of the DPOs were staged. All of the bilateral surgeries had the initial and subsequent surgeries performed at the MU-VMTH as well. No dog had both a TPO and DPO.

Intraoperative complications occurred with both techniques. There were five intraoperative complications for the TPO, all of which were osteotomies performed over the sacrum (too far cranial) as opposed to just caudal to the sacrum as recommended.¹³⁴ Four of those five complications occurred with cases operated by residents, three of which were unsupervised per medical record review. There were only 2 intraoperative complications for DPO. One was an osteotomy performed over the sacrum by a faculty surgeon, the other was an under rotated osteotomy that was observed on postoperative radiographs.

Complications of pelvic osteotomy discovered at recheck examination appear to occur more commonly than intraoperative ones. Minor TPO complications occurred 46.6% of the time (Fig. 3-2) and included persistent hip pain, ischial tuberosity fracture, 5 incidences of cranial segment screw loosening, and 3 broken ischial hemicerclage wires.

There were two major complications for TPO in which cranial screw loosening resulted in complete implant failure (13.3% major complication rate) (Fig. 3-2). Both instances of complete implant failure occurred on the second surgery in cases with staged bilateral procedures and cranially malpositioned ilial osteotomies performed by unsupervised residents. There was an overall complication rate of 59.9% for TPO (Fig. 3-2). Follow up times for both groups were similar, 6.4 ± 7.9 for TPO and 4.8 ± 7.2 (months \pm SD) for DPO.

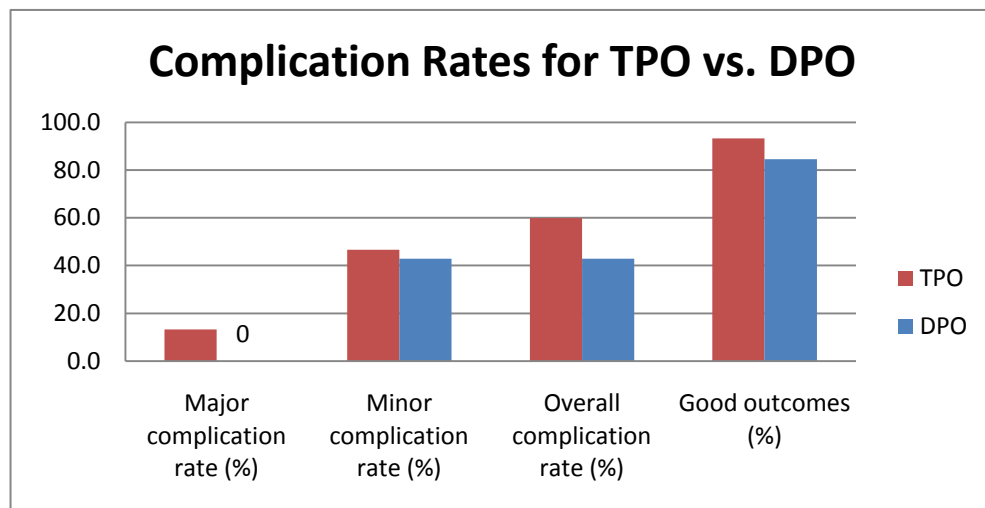


Figure 3-2. Bar graph comparing complication rates and outcome of patients having either a triple pelvic osteotomy (TPO) or double pelvic osteotomy (DPO).

Double pelvic osteotomy did not have a single major complication. There was a 42.9% minor complication rate (Fig. 3-2) including screw loosening in three cases (one cranial segment, two caudal), the development of osteoarthritis in two cases (one clinically affected), two cases of unilateral neuropraxia, and one inguinal incision dehiscence. In the cases of neuropraxia, one was thought to be related to complications

from preoperative epidural administration, the other had implant loosening of the caudal segment as well. None of the DPOs were performed by unsupervised residents.

None of TPOs were double plated, but 4 of the DPOs had an additional 2.7 mm dynamic compression plate applied ventrally (3), or dorsal to the CPOP on the lateral surface of the ilium. None of the double plated cases had major complications, despite one of the cases having a cranially malpositioned osteotomy.

Of the DPOs with complications, 3 of them could be contributed to under rotation of the acetabular segment. Two dogs developed coxofemoral OA after healed osteotomies, and one dog had continued laxity of the coxofemoral joint. All three of these dogs had DPOs performed with 20° plates.

Overall, 93.3% of TPOs and 84.6% of DPOs resulted in a good outcome as determined by medical record review. One case from each surgery type did not have any follow up and thus were excluded from that analysis.

Discussion

In comparing the complication rates between DPO and TPO, DPO had a lower overall complication rate of 42.9% compared to 59.9% for DPO, both of which are very similar to that reported in the literature.^{136,140,141} Perhaps more important, DPO far surpassed TPO by not having a single major complication. Of the two major complications of TPO, one resolved after a single revision surgery, while the second required two revisions. The lower complication rate of DPO is more impressive considering the technique was examined in this study during the first 14 cases performed at the MU-VMTH, and thus was during a learning curve for the technique. Improper plate selection may have been part of that learning process. Based on the results of

Haudiquet and from our findings in Chapter 2, the recommended ventroversion for DPO is 25°. Three of the minor complications of DPO could be related to lack of sufficient ventroversion. Twenty-degree plates were used in 2 cases that subsequently developed OA, and another dog had persistent hip laxity that might have benefitted more from a 25° or 30° plate. The development of OA is the only complication for one of the cases. If that case was prevented from having a complication by using an appropriate plate size, the overall complication rate for DPO would have been 35.7%, similar to the lowest complication rate ever reported for TPO (29%).¹⁴⁶ Interestingly, two of these cases were the only ones given “not good” values for outcome scoring for DPO. Perhaps, using an appropriate size plate would have given the DPO a better outcome score as well.

It is important to recognize factors in this study that could have given DPO an advantage. The use of a 2.7 mm DCP applied ventrally in addition to the CPOP plate has been shown to be stronger biomechanically and significantly decrease implant related complication rates following TPO.^{145,161} In the current study, none of the TPO cases were supported by an additional plate, but 4 of the 14 DPOs were. None of those 4 cases had any implant related complications. One of those cases had a cranially malpositioned osteotomy, but did not have any complications at recheck examination, potentially due to the addition of the second plate. When the double plated DPOs are removed from analysis, the total DPO complication rate increases to 50%.

Another difference between the TPO and DPO groups that may account for the different complication rates may be the experience of the primary surgeons. Faculty surgeons performed more than twice the number of DPOs compared to TPOs (64% to 26.7%, respectively). It has been shown that surgeon experience decreases the

complication rate of total hip replacements in veterinary medicine.¹²⁰ While a similar study has not been done for pelvic osteotomy surgery, one might expect similar results. The thought that surgeon experience might have influenced complication rates in this study is supported by the fact that cranially malpositioned ilial osteotomies were the most common intraoperative complication in both the TPO and DPO groups. Four of the 6 cranial osteotomies were performed by residents, 3 of which were unsupervised in surgery. More telling is the fact that both TPO cases of cranial screw loosening that resulted in implant failure and revision surgery were performed by unsupervised residents. Interestingly, both of these surgeries were the second TPO performed in a staged fashion for the patient after a successful initial surgery. This fact might support the idea that patient or client factors did not contribute to surgical failure. However, with such a low number of cases in this study, any conclusions drawn from these facts would be mere speculation.

Unexpectedly, this study highlights cranially malpositioned ilial osteotomy as a potential cause for complications with pelvic osteotomy surgery that has not been discussed previously in the veterinary literature. Four of 6 cases with cranial osteotomies had implant complications (screw loosening or hemicerclage breakage). One of the two cases without complications was potentially protected from complication by double plating at the time of surgery. The canine ilium becomes much flatter and broader almost immediately cranial to the ilial body where it articulates with the sacrum and transitions into the ilial crest. This thinner portion of the ilium probably allows for a lower volume of screw/bone interface and thus decreased implant security. By making the osteotomy over the sacrum, less sacrum is then available for cranial screw purchase, increasing the

risk of implant complications. This theory is supported by the fact that osteotomies made over the sacrum resulted in cranial screw loosening 50% of the time. Current recommendations to prevent cranial screw loosening include increased sacral purchase to greater than 1 cm with at least two of the cranial screws, the use of cancellous screws, and the use of self-tapping screws in the cranial segment.^{143,144,147} Perhaps proper location of osteotomies caudal to the sacrum should be included on that list as well.

Sacrospinous ligament transection was an early recommendation that has since been abandoned.¹⁰⁶ In reviewing the small number of DPOs performed in this study without ST transection, there does not appear to be a difference in surgical complication or outcome. One of the cases without ST transection continued to have CF joint laxity and a “not good” scoring; however, that case also had a 20° plate that may have contributed to under rotation. Additionally, two of the four cases without ST transection were double plated, which could have decreased their likelihood of complication. Due to the low case numbers, it is difficult to comment on ST transection from this study except to say that it is feasible to perform and can result in good outcomes.

Another purported advantage of the DPO over TPO is the ability to perform the procedure bilaterally in a single session. There was not a single DPO performed bilaterally as a single procedure in this study; therefore, conclusions about feasibility or outcomes cannot be made. However, it was interesting to note the need for single session bilateral procedures in the cases included in this study. Two cases from each group (4 total) were identified as candidates for bilateral pelvic osteotomy at initial evaluation, but the opportunity was lost during recovery from the first surgery. Osteoarthritis progressed enough in the second hip of these dogs that they were considered to not be candidates for

a second pelvic osteotomy at 4 week reevaluation. Two additional cases were recommended to have a second procedure performed, but the owners declined a second surgery. These 6 dogs represent 37.5% of the dogs that could have benefitted from a bilateral procedure initially, but received unilateral instead. Since these findings are based on medical record review, it is very possible that these numbers are an underestimation. Vezzoni et al report that bilateral DPO in clinical patients has a complication rate that is lower than unilateral TPO and that patients with bilateral DPO are comfortable and ambulate well after surgery.¹⁰⁶ If these observations hold true in future studies, the ability to perform bilateral DPO could be a significant improvement in pelvic osteotomy for CHD.

Strengths of this study include the fact that surgeons at the MU-VMTH almost simultaneously adopted the DPO, eliminating patient selection bias from the study, the surgeons performed the technique fairly uniformly, and the two groups seem very well matched in age and weight. However, due to the retrospective nature of this study design, there are significant limitations that must be considered when evaluating its results. Differences in surgeon experience, plate selection, the use of double plating with only DPO, and limited recheck time all weaken the strength of this study. The small number of cases also makes data analysis extremely difficult and inductive statistics impossible.

Despite these limitations, there are a number of findings in this study that support the continued use of DPO over TPO. Double pelvic osteotomy had no major complications in the first 14 cases performed at the MU-VMTH, and had a lower complication rate overall compared to TPO. In order to prevent complications, the

findings of this study support the use of a 30° plate (over a 20° plate), ventral plating with a 2.7 mm DCP, and surgeries performed by faculty members or residents under direct supervision. Sacrotuberous ligament transection does not seem to be necessary for successful outcomes, and there were a number of cases that could have benefited from successful bilateral pelvic osteotomy surgery. In summary, it seems that at the MU-VMTH, DPO has had good success in the past and with the improvements in the technique outlined by this study, could have still greater success in the future.

Chapter 4

Conclusions and Future Directions

Because canine hip dysplasia is the most common developmental orthopedic disease in dogs and causes dysfunction and pain, veterinary medicine has devoted much time and energy into researching the etiology and potential treatments.²⁻⁹ In some areas, like surgical treatment for CHD, there has been good progress. Currently, there are a number of total hip replacement systems that can provide excellent treatment for end stage coxofemoral OA with greater than 90% success.^{118,121,122} Juvenile pubic symphysiodesis has been well researched and proven to prevent OA in dogs predisposed to CHD.^{77,78,110} However, TPO has seemed to lag in its development until recently. With complication rates of 33-50% and euthanasia as a reported outcome, results have deterred some veterinary surgeons from recommending the technique.^{140,141,145}

The advent of the DPO and its potential advantages has brought renewed interest to the idea of pelvic osteotomy surgery for the prevention of coxofemoral OA secondary to CHD. Intuitively, it makes sense that making fewer osteotomies of the pelvis would result in a more stable final construct. This stability could potentially translate into a lower implant migration rate and the ability to perform the procedure bilaterally in a single session without worry of increased complication risk. The feasibility of a bilateral procedure would be of great benefit with pelvic osteotomy for CHD since delays in surgery could potentially lead to lifelong OA if the surgery is not performed in the early stages of the disease. A final and convincing advantage to the DPO would be if it provided decreased patient pain postoperatively as well.

In the sole peer reviewed clinical study of DPO, some of the projected advantages of DPO seem to be holding true. Vezzoni, et al report high efficacy of the procedure with implant complication rates less than half what is reported for TPO. These findings are made more impressive by the fact that 20 had bilateral single session surgeries.¹⁰⁶

Since the DPO is gaining in popularity for clinical use, elucidating the differences between TPO and DPO so that the DPO can become refined as a clinical technique is important. Haudiquet & Guillion recommended using a 25° plate instead of 20° as previously recommended.^{150,152} However, their radiographic study did not evaluate how the DPO caused ventroversion of the acetabulum without making an ischial osteotomy.¹⁵²

Our *in vitro* study used CT examination of operated pelvises to measure the degree of ventroversion with 3° of axial rotation for DPO compared to TPO at 20°. Our findings support Haudiquet's recommendation of 25° axial rotation with the DPO to mimic the previous results of 20° TPO. Additionally, we found that the vast majority of the axial rotation induced in the pelvis by DPO comes at the level of the pubic symphysis. This knowledge should bring comfort to the surgeon performing the technique in knowing that the rotation is induced caudal to the acetabulum and therefore should effectively increase coverage of the dysplastic femoral head. Since JPS fuses the pelvic symphysis, our study may also contraindicate DPO as a procedure for patients with previously performed JPS. Finally, our study might also suggest that in patients that are difficult to ventrally rotate the ilium at surgery, incision into the pubic symphysis itself might be more helpful than ischial osteotomy or sacrotuberous ligament transaction as previously recommended.

Our retrospective study found that at the MU-VMTH, the recent adoption of DPO over TPO has resulted in decreased overall complication rates, and the elimination of major complications thus far. The study supports surgery by faculty members or directly supervised residents using a 30° plate, double plating with an additional DCP, and a well positioned ilial osteotomy to decrease complications rates.

Being a study of only 29 cases and poorly controlled, this study certainly has flaws that cannot be overlooked. There are additional studies that can be performed in the future that would give us more information about the DPO and its potential advantages.

The major purported advantage of the DPO over TPO is that the DPO is more inherently stable, though there is a complete lack of evidence to support this claim. To test this theory, a biomechanical *in vitro* comparison of DPO and TPO would provide useful information in this regard. The study could be conducted similarly to a study by Fitch et al to compare TPO with and without ventral plate stabilization. In the Fitch study, however, single hemipelvises of young large breed dogs were used in biomechanical testing.¹⁶¹ In order to compare DPO to TPO, the pelvis will need to be kept intact at the symphysis and probably the sacrum as well. But, the Fitch study does provide good baseline technique information about acetabular displacement (6 mm), frequency (1 Hz), and cycles (900) with which to compare. Cycling both sides of an intact pelvis with 2 separate impingement rods to mimic the shift of load from one hemipelvis to the other would be ideal, though perhaps not entirely necessary. Despite the DPO being recommended as a single session bilateral technique, comparing TPO to DPO on only one hemipelvis might be a more comparable model since TPO is recommended as a

unilateral technique. Significance was found in screw loosening between the two groups with 6 samples per group in the previous study, and would be a good number for this proposed study as well.¹⁶¹ Triple pelvic osteotomy and DPO have traditionally been performed with the CPOP plate. The same plate was used in the Fitch study as well. In this proposed study, DPO and TPO might be compared with CPOP as two groups, but a third group could be added as well. New Generation Devices[®] has developed a plate specifically for the DPO procedure (Fig. 4-1). The proposed advantage of this device is that it has 4 screw holes cranially and 4 caudally. The dorsal two screw holes on either side accommodate locking screws in a divergent arrangement in an effort to prevent implant loosening by screw back out.¹⁰⁶ Inclusion of this third group would enable the study to compare the new implant to the traditional CPOP to see if the implant might be an improvement in the DPO technique as well. Measurements in this study would be made identically to the Fitch paper.¹⁶¹ Stiffness of the constructs could be compared prior to cyclic loading, and screw loosening would be identified in each screw location and quantified in the number of turns to retighten each screw.



Figure 4-1. Photo of the New Generation Devices Double Pelvic Osteotomy Plate. Printed with permission NGD 2011.

A biomechanical test of the two procedures may provide good information on the mechanical stability of the two procedures, but in order to test the clinical effects of each on implant-related complications, ability to prevent progression of OA secondary to CHD, and level of postoperative discomfort, a controlled cohort study would be necessary. In this study, related puppies predisposed to CHD would be used. They would be divided into the two groups based on DI scoring and presence of OA so that both groups had statistically similar distribution of DI scores, and theoretically the same risk for coxofemoral OA. The puppies would be fed the same amounts of an identical diet and housed identically. Surgery would be performed unilaterally, either TPO or DPO, at 6 months of age for all dogs. Arthroscopic scoring with the modified Outerbridge score of the coxofemoral joint would be performed at the time of surgery.⁹²

Anesthesia and postoperative pain management would be performed the same for both groups. Pain would be scored by a visual assessment score by an individual blinded to the surgical procedure, and an incision over the ischium could be made in DPO patients as well to aid in blinding. This score and force plate analysis could be made at multiple time points for the first 3 days after surgery, then daily for 10 days in an effort to compare the comfort level of dogs between the two procedures.¹⁶² Radiographs would be taken at 10 days, 1, 2, and 6 months after surgery to evaluate for osteotomy healing, complications, and progression of osteoarthritis. Arthroscopy would be performed again at 2, 6, 12, and 24 months to evaluate the CF joint for degenerative joint disease that might not be readily apparent radiographically. The goal of this study would be to compare the TPO and DPO in a well controlled head to head study to see how each prevents the progression of osteoarthritis based on radiographs and arthroscopy, complication rates for each, and the postoperative pain for each surgery. Despite the large expense and effort this study would entail, it would be the best study to compare the two techniques.

In summary, canine hip dysplasia is a serious orthopedic disease in dogs without a single ideal treatment to date. However, based on recent peer-reviewed data and the retrospective study reported here, DPO seems to be an improvement over the TPO for treatment of young dogs that have missed the early, small window for JPS, but before the development of coxofemoral OA. The studies presented in this thesis have brought new data into the discussion of how DPO favorably alters canine anatomy to treat early CHD, and the potential clinical benefits of DPO over TPO. However, there is still much work to be done to prove that DPO is a safe and more effective treatment than its preceding

technique. It is our hope that veterinary surgery can continue to evolve to bring more comfort to dogs affected by CHD.

REFERENCES

1. Schnelle GB: Congenital subluxation of the coxofemoral joint in a dog. University of Pennsylvania Bulletin 15, 1935.
2. Zhang Z, Zhu L, Sandler J, et al: Estimation of heritabilities, genetic correlations, and breeding values of four traits that collectively define hip dysplasia in dogs. Am J Vet Res 70:483-492, 2009.
3. van Hagen MAE, Ducro BJ, Broek J, et al: Incidence, risk factors, and heritability estimates of hind limb lameness caused by hip dysplasia in a birth cohort of boxers. Am J Vet Res 66:307-312, 2005.
4. Paster ER, LaFond E, Biery DN, et al: Estimates of prevalence of hip dysplasia in Golden Retrievers and Rottweilers and the influence of bias on published prevalence figures. J Am Vet Med Assoc 226:387-392, 2005.
5. Witsberger TH, Villamil JA, Schultz LG, et al: Prevalence of and risk factors for hip dysplasia and cranial cruciate ligament deficiency in dogs. J Am Vet Med Assoc 232:1818-1824, 2008.
6. Rettenmaier J, Keller G, Lattimer J, et al: Prevalence of canine hip dysplasia in a veterinary teaching hospital population. Vet Radiol Ultrasound 43:313-318, 2002.
7. Smith GK, Biery DN, Iriye A: Frequency of hip dysplasia in golden retrievers and rottweilers and the effect of prescreening of radiographs on reported CHD prevalence figures, Proceedings, Vet Orthop Soc Ann Conf, 1997 (available from
8. Comhaire FH, Snaps F: Comparison of two canine registry databases on the prevalence of hip dysplasia by breed and the relationship of dysplasia with body weight and height. Am J Vet Res 69:330-333, 2008.
9. Coopman F, Verhoeven G, Saunders J, et al: Prevalence of hip dysplasia, elbow dysplasia and humeral head osteochondrosis in dog breeds in Belgium. Vet Rec 163:654-658, 2008.
10. Smith GK, Biery DN, Gregor TP: New concepts of coxofemoral joint stability and the development of a clinical stress-radiographic method for quantitating hip joint in the dog. J Am Vet Med Assoc 196:59-70, 1990.
11. Smith GK, Gregor TP, Rhodes WH: Coxofemoral joint laxity from distraction radiography and its contemporaneous and prospective correlation with laxity, subjective score, and evidence of degenerative joint disease from conventional hip-extended radiography in dogs. Am J Vet Res 54:1021-1042, 1993.
12. Smith GK, LaFond E, Gregor TP: Biomechanical characterization of passive laxity of the hip joint in dogs. Am J Vet Res 58:642-647, 1997.
13. Smith GK, LaFond E, Gregor TP: Within- and between-examiner repeatability of distraction indices of the hip joints in dogs. Am J Vet Res 58:1076-1078, 1997.
14. Smith GK, Popovitch CA, Gregor TP: Evaluation of risk factors for degenerative joint disease associated with hip dysplasia in dogs. J Am Vet Med Assoc 206:642-647, 1995.
15. Katic N, Bockstahler BA, Mueller M, et al: Fourier analysis of vertical ground reaction forces in dogs with unilateral hind limb lameness caused by degenerative disease of the hip joint and in dogs without lameness. Am J Vet Res 70:118-126, 2009.

16. Moore GE, Burkman KD, Carter MN, et al: Causes of death or reasons for euthanasia in military working dogs: 927 cases (1993-1996). *J Am Vet Med Assoc* 219:209-214, 2001.
17. Smith GK, Paster ER, Powers MY, et al: Lifelong diet restriction and radiographic evidence of osteoarthritis of the hip joint in dogs. *J Am Vet Med Assoc* 229:690-693, 2006.
18. Iwata D, Broun H, Black A, et al: Total hip arthroplasty outcomes assessment using functional and radiographic scores to compare canine systems. *Vet Comp Orthop Tramadol* 21:221-230, 2008.
19. Leighton EA: Genetics of canine hip dysplasia. *J Am Vet Med Assoc* 210:1474-1479, 1997.
20. Riser WH: The dysplastic hip joint: Its radiographic and histologic development. *J Am Vet Radiol Soc* 14:35, 1973.
21. Morgan SJ: The pathology of canine hip dysplasia. *Vet Clin North Am Small Anim Pract* 22:541-549, 1992.
22. Kammerman JR, Kincaid SA, Rumph PF: Tumor necrosis factor in canine osteoarthritis: immunolocalization of TNA-a, stromelysin and TNF receptors in canine osteoarthritic cartilage. *Osteoarthritis Cartilage* 4:23-43, 1996.
23. Friedman MA, Eisenberg RA, Wright PH: Osteoarthritis, in Wilson FC (ed): *The Musculoskeletal System Basic Processes and Disorders* (ed 2), Vol. Philadelphia, J.B. Lippincott, 1983.
24. Alexander JW: The pathogenesis of canine hip dysplasia. *Vet Clin North Am Small Anim Pract* 22:503-511, 1992.
25. Morgan SJ: Pathologic alternation in canine hip dysplasia. *J Am Vet Med Assoc* 210:1446-1450, 1997.
26. Farese JP, Lust G, Williams AJ, et al: Comparison of measurements of dorsolateral subluxation of the femoral head and maximal passive laxity for evaluation of the coxofemoral joint in dogs. *Am J Vet Res* 60:1571-1576, 1999.
27. Grant ME, Prockop DJ: The biosynthesis of collagen. *N Engl J Med* 286:291-300, 1972.
28. Madsen JS: The joint capsule and joint laxity in dogs with hip dysplasia. *J Am Vet Med Assoc* 210:1463-1465, 1997.
29. Epstein EH: Alpha 1 (III)3 Human skin collagen *J Biol Chem* 249:3225-3231, 1974.
30. Cardinet GH, Kass PH, Wallace LJ, et al: Association between pelvic muscle mass and canine hip dysplasia. *J Am Vet Med Assoc* 210:1466-1473, 1997.
31. Engel WK, Karpati G: Impaired skeletal muscle maturation following neonatal neurectomy. *Dev Biol* 18:447-455, 1968.
32. Reimann I, Vittas D, Nielsen SL, et al: Lymphatic transport from normal and synovitic knees in rabbits. *Acta Orthop Scand* 60:185-187, 1989.
33. Lust G, Summers BA: Early, asymptomatic stage of degenerative joint disease in canine hip joints. *Am J Vet Res* 42:1849-1855, 1981.
34. Lust G, Beilman WT, Rendano VT: A relationship between degree of laxity and synovial fluid volume in coxofemoral joints of dogs predisposed for hip dysplasia. *Am J Vet Res* 41:55-60, 1980.
35. Lust G, Williams AJ, Burton-Wurster N, et al: Joint laxity and its association with hip dysplasia in Labrador Retrievers. *Am J Vet Res* 54:1990-1999, 1993.

36. Vezzoni A, Dravelli G, Vezzoni L, et al: Comparison of conservative management and juvenile pubic symphysiodesis in the early treatment of canine hip dysplasia. *Vet Comp Orthop Traumatol* 21:267-279, 2008.
37. Riser W: Growth and development of the normal canine pelvis, hip joints, and femur from birth to maturity. *Vet Pathol* 12:264-278, 1975.
38. Wilkinson JA: Congenital displacement of the hip joint. Berlin, Springer-Verlag, 1985.
39. Allhands RV, Kallfelz FA, Lust G: Radionuclide joint imaging: an ancillary technique in the diagnosis of canine hip dysplasia. *Am J Vet Res* 41:230-233, 1980.
40. Todhunter RJ, Zachos TA, Gilbert RO, et al: Onset of epiphyseal mineralization and growth plate closure in radiographically normal and dysplastic Labrador retrievers. *J Am Vet Med Assoc* 210:1458-1462, 1997.
41. Hedhammar A, Wu F, Krook L, et al: Overnutrition and skeletal disease: an experimental study in growing Great Dane dogs. *Cornell Vet* 64:1-160, 1974.
42. Hedhammar A, Olsson SE, Andersson SA, et al: Canine hip dysplasia: study of heritability in 401 litters of German Shepherd dogs. *J Am Vet Med Assoc* 174:1012-1016, 1979.
43. Ginja MMD, Silvestre AM, Gonzalo-Orden JM, et al: Diagnosis, genetic control and preventive management of canine hip dysplasia: A review. *Vet J* 184:269-276, 2010.
44. Mäki K, Janss LL, Groen AF, et al: An indication of major genes affecting hip and elbow dysplasia in four Finnish dog populations. *Heredity* 92:402-408, 2004.
45. Hou Y, Wang Y, Lust G, et al: Retrospective analysis for genetic improvement of hip joints of cohort labrador retrievers in the United States: 1970–2007. *PLoS ONE* 5:579-593, 2010.
46. Lust G: An overview of the pathogenesis of canine hip dysplasia. *J Am Vet Med Assoc* 210:1443-1445, 1997.
47. Friedenberg SG, Zhu L, Zhang Z, et al: Evaluation of a fibrillin 2 gene haplotype associated with hip dysplasia and incipient osteoarthritis in dogs. *Am J Vet Res* 72:530-540, 2011.
48. Tsai KL, Murphy KE: Clinical and genetic assessments of hip joint laxity in the Boykin spaniel. *Can J Vet Res* 70:148-150, 2006
49. Olsson SE: Roentgen examination of the hip joints of German Shepherd Dogs. *Adv Small Anim Pract* 3:117-118, 1961.
50. Breur GJ, Lust G, Todhunter RJ: Chapter 9: Genetics of hip dysplasia and other orthopedic traits, in Ruvinsky A, Sampson J (eds): *Genetics of the dog*, Vol. Wallingford, England, CAB International, 2002.
51. Salmeri KR, Bloomberg MS, Scruggs SL, et al: Gonadectomy in immature dogs: effects on skeletal, physical, and behavioral development. *J Am Vet Med Assoc* 198:1193-1203, 1991.
52. Root MV, Johnston SD, Olson PN: The effect of prepuberal and postpuberal gonadectomy on radial physeal closure in male and female domestic cats. *Vet Radiol Ultrasound* 38:42-47, 1997.
53. Craig LE: Physeal dysplasia with slipped capital femoral epiphysis in 13 cats. *Vet Pathol* 38:92–97, 2001.

54. McNicholas WT, Wilkens BE, Blevins WE, et al: Spontaneous femoral capital physal fractures in adult cats: 26 cases (1996–2001). *J Am Vet Med Assoc* 221, 2002.
55. Van Hagen MA, Ducro BJ, Van Den Broek J, et al: Incidence, risk factors, and heritability estimates of hind limb lameness caused by hip dysplasia in a birth cohort of boxers. *Am J Vet Res* 66:307-312, 2005.
56. Xu RJ: Development of the newborn GI tract and its relation to colostrum/milk intake: A review. *Reprod Fertil Dev* 8:35-48, 1996.
57. Goldsmith LT, Lust G, Steinetz BG: Transmission of relaxin from lactating bitches to their offspring via suckling. *Biol Reprod* 50:258-265, 1994.
58. Steinetz BG: Transmission of estrogen and relaxin to suckling pups via milk: A possible role of hormones in canine hip dysplasia, Proceedings, Meeting of the Endocrinology Society, 1997 (available from
59. Samuel C: The effect of relaxin on collagen metabolism in the nonpregnant rat pubic symphysis: The role of estrogen and progesterone on relaxin activity. *Endocrinology* 137:3884-3890, 1996.
60. Riser WH, Cohen D, Lindquist S, et al: Influence of rapid growth and weight gain on hip dysplasia in the German Shepherd dog. *J Am Vet Med Assoc* 145:661-668, 1964.
61. Kasstrom H: Nutrition, weight gain, and development of hip dysplasia. *Acta Radiologica* 334 (supp):135-117, 1975.
62. Kealy RD, Lawler DF, Ballam JM, et al: Evaluation of the effect of limited food consumption on radiographic evidence of osteoarthritis in dogs. *Journal of the American Veterinary Medical Association* 217:1678-1680, 2000.
63. Kealy RD, Lawler DF, Ballam JM, et al: Effects of diet restriction on life span and age-related changes in dogs. *Journal of the American Veterinary Medical Association* 220:1315-1320, 2002.
64. Lawler DF, Evans RH, Larson BT, et al: Influence of lifetime food restriction on causes, time, and predictors of death in dogs. *Journal of the American Veterinary Medical Association* 226:225-231, 2005.
65. Smith GK, Paster ER, Powers MY, et al: Lifelong diet restriction and radiographic evidence of osteoarthritis of the hip joint in dogs. *Journal of the American Veterinary Medical Association* 229:690-693, 2006.
66. Lust G, Redano VT, Summers BA: Canine hip dysplasia: Concepts and diagnosis. *J Am Vet Med Assoc* 187:638-640, 1985.
67. Tvedten HW, Carrig CB, Flo GL, et al: Incidence of hip dysplasia in Beagle dogs fed different amounts of protein and carbohydrate. *J Am Anim Hosp Assoc* 13:595-598, 1977.
68. Resnick S: Effect of an all-meat diet and high-carbohydrate diet on hip conformation in dogs. *Vet Med/ Small An Clin*:739-743, 1974.
69. Belfield WO: Chronic subclinical scurvy and canine hip dysplasia. *Vet Med/ Small An Clin*:1399-1403, 1976.
70. Cunningham JG, Klein BG: *Textbook of Veterinary Physiology* (ed 4), Saunders 2007.

71. Hazewinkel HAW, Goedegebuure SA, Poulos PW, et al: Influences of chronic calcium excess on the skeletal development of growing Great Danes. *J Am Anim Hosp Assoc* 21:377-391, 1985.
72. Fries CL, Remedios AM: Treatment of canine hip dysplasia: a review. *Can Vet J* 36:503-509, 1995.
73. Kapatkin AS, Fordyce HH, Mayhew PD, et al: Canine hip dysplasia: the disease and its diagnosis. *Comp Cont Edu Pract* 24:526-536, 2002.
74. Ortolani M: Congenital hip dysplasia in the light of early and very early diagnosis. *Clin Orthop* 119:6-10, 1976.
75. Johnson AL, Smith CW, Pijanowski GJ, et al: Triple pelvic osteotomy: effect on limb function and progression of degenerative joint disease. *J Am Anim Hosp Assoc* 34:260-264, 1998.
76. McLaughlin RM, Jr., Miller CW, Taves CL, et al: Force plate analysis of triple pelvic osteotomy for the treatment of canine hip dysplasia. *Vet Surg* 20:291-297, 1991.
77. Dueland RT, Adams WM, Fialkowski JP, et al: Effects of pubic symphysiodesis in dysplastic puppies. *Vet Surg* 30:201-217, 2001.
78. Patricelli AJ, Dueland RT, Adams WM, et al: Juvenile pubic symphysiodesis in dysplastic puppies at 15 and 20 weeks of age. *Vet Surg* 31:435-444, 2002.
79. Corley EA: Role of the orthopedic foundation for animals in the control of canine hip dysplasia. *Vet Clin North Am Small Anim Pract* 22:579-593, 1992.
80. Barlow TG: Early diagnosis and treatment of congenital dislocation of the hip *J Bone Joint Surg Br* 44-B:292-301, 1962.
81. Bardens JW: Palpation for the detection of joint laxity, Proceedings, Proc Canine Hip Dysplasia Symp Workshop, 1973 (available from
82. Slocum B, Devine TM: Dorsal acetabular rim radiographic view for evaluation of the canine hip. *J Am Anim Hosp Assoc* 26:289-296, 1990.
83. Charlette B, Dupuis J, Beauregard G, et al: Palpation and dorsal acetabular rim radiographic view for early detection of canine hip dysplasia. *Vet Comp Orthop Traumatol* 14:125-132, 2001.
84. Puerto DA, Smith GK, Gregor TP, et al: Relationships between the results of the Ortolani method of hip joint palpation and distraction index, Norberg angle, and hip score in dogs. *J Am Vet Med Assoc* 214:497-501, 1999.
85. Powers MY, Karbe GT, Gregor TP, et al: Evaluation of the relationship between Orthopedic Foundation for Animals' hip joint scores and PennHIP distraction index values in dogs. *J Am Vet Med Assoc* 237:532-541, 2010.
86. Whittington K, Banks WC, Carlson WD, et al: Report of panel on canine hip dysplasia. *J Am Vet Med Assoc* 139:791-806, 1961.
87. Gibbs C: The BVA/KC scoring scheme for control of hip dysplasia: Interpretation criteria. *Vet Rec* 141:275-284, 1997.
88. Owens JM, Biery DN: Radiographic Interpretation for the Small Animal Clinician (ed 2). Baltimore, Williams & Wilkins, 1999.
89. Powers MY, Biery DN, Lawler DF, et al: Use of the caudolateral curvilinear osteophyte as an early marker for future development of osteoarthritis associated with hip dysplasia in dogs. *J Am Vet Med Assoc* 225:233-237, 2004.

90. Risler A, Klauer JM, Keuler NS, et al: Puppy Line, Metaphyseal Sclerosis, and Caudolateral Curvilinear and Circumferential Femoral Head Osteophytes in Early Detection of Canine Hip Dysplasia. *Vet Radiol Ultrasound* 50:157-166, 2009.
91. Szabo SD, Biery DN, Lawler DF, et al: Evaluation of a circumferential femoral head osteophyte as an early indicator of osteoarthritis characteristic of canine hip dysplasia in dogs. *J Am Vet Med Assoc* 231:889-892, 2007.
92. Holsworth IG, Schulz KS, Kass PH, et al: Comparison of arthroscopic and radiographic abnormalities in the hip joints of juvenile dogs with hip dysplasia. *J Am Vet Med Assoc* 227:1087-1094, 2005.
93. Lust G, Todhunter RJ, Erb HN, et al: Comparison of three radiographic methods to measure passive hip laxity in the dog. *J Am Vet Med Assoc* 219:1242-1246, 2001.
94. Corr S: Hip dysplasia in dogs: treatment options and decision making. *In Practice* 29:66-75, 2007.
95. Sandersoln R, Beata C, Flipo R, et al: Systematic review of the management of canine osteoarthritis. *Vet Rec* 164:418-424, 2009.
96. Steinetz BG, Williams AJ, Lust G, et al: Transmission of relaxin and estrogens to suckling canine pups via milk and possible association with hip joint laxity. *Am J Vet Res* 69:59-67, 2008.
97. Barr ARS, et al: Clinical hip dysplasia in growing dogs: the long-term results of conservative management. *J Sm An Pract* 28:243-252, 1987.
98. Farrell M, Clements D, Mellor D, et al: Retrospective evaluation of the long-term outcome of non-surgical management of 74 dogs with clinical hip dysplasia. *Vet Rec* 160:506-511, 2007.
99. Lust G, Williams AJ, Burton-Wurster N, et al: Effects of intramuscular administration of glycosaminoglycan polysulfates on signs of incipient hip dysplasia in growing pups. *Am J Vet Res* 53:1836-1843, 1992.
100. Henrotin Y, Sanchez C, Balligand M: Pharmaceutical and nutraceutical management of canine osteoarthritis: present and future perspectives. *Vet J* 170:113-123, 2005.
101. Bergh MS, Budsberg SC: The coxib NSAIDs: potential clinical and pharmacologic importance in veterinary medicine. *J Vet Intern Med* 19:633-643, 2005.
102. Lockwood AA, Liska WD: Duration of clinical signs prior to total hip replacement in dogs. *J Am Vet Med Assoc* 238:905-908, 2011.
103. Manley PA, Adams WM, Danielson KC, et al: Long-term outcome of juvenile pubic symphysiodesis and triple pelvic osteotomy in dogs with hip dysplasia. *J Am Vet Med Assoc* 230:206-210, 2007.
104. Wallace LJ: Pectineus tendon surgery for the management of canine hip dysplasia. *Vet Clin North Am Small Anim Pract* 3:607-621, 1992.
105. Braden TD, Prieur WD, Kaneene JB: Clinical evaluation of intertrochanteric osteotomy for treatment of dogs with early-stage hip dysplasia: 37 cases (1980-1987). *J Am Vet Med Assoc* 196:337-341, 1990.
106. Vezzoni A, Boiocchi S, Vezzoni L, et al: Double pelvic osteotomy for the treatment of hip dysplasia in young dogs. *Vet Comp Orthop Tramadol* 23:444-452, 2010.
107. Slocum B: Triple pelvic osteotomy. *J Am Anim Hosp Assoc* 34:361-363, 1998.

108. Lascelles BDX, Freire M, Roe SC, et al: Evaluation of Functional Outcome After BFX® Total Hip Replacement Using a Pressure Sensitive Walkway. *Vet Surg* 39:71-77, 2010.
109. Berzon J, Howard P, Covell S, et al: A retrospective study of the efficacy of femoral head and neck excisions in 94 dogs and cats. *Vet Surg* 9:88-92, 1980.
110. Patricelli AJ, Dueland RT, Lu Y, et al: Canine pubic symphysiodesis: investigation of electrocautery dose response by histologic examination and temperature measurement. *Vet Surg* 30:261-268, 2001.
111. Berzon JL, Howard PE, Covell SJ, et al: A retrospective study of the efficacy of femoral head and neck excisions in 94 dogs and cats. *Vet Surg* 9:88-92, 1980.
112. Mann FA, Tangner CH, Wagner-Mann C, et al: A comparison of standard femoral head and neck excision and femoral head and neck excision using a biceps femoris muscle flap in the dog. *Vet Surg* 16:223-230, 1987.
113. Montgomery RD, Milton JL, Horne RD, et al: A retrospective comparison of three techniques for femoral head and neck excision in dogs. *Vet Surg* 16:423-426, 1987.
114. Duff R, Campbell JR: Long term results of excision arthroplasty of the canine hip. *Vet Rec* 101:181-184, 1977.
115. Grisneaux DE, Dupuis J, Pibarot P, et al: Effects of postoperative administration of ketoprofen or carprofen on short- and long-term results of femoral head and neck excision in dogs. *J Am Vet Med Assoc* 223:1006-1012, 2003.
116. Carpenter LG, Oulton SA, Piermattei DL: Femoral head and neck excision in a dog that had previously undergone contralateral hind limb amputation. *J Am Vet Med Assoc* 208:695-696, 1996.
117. Skurla CT, Egger EL, Schwarz PD, et al: Owner assessment of the outcome of total hip arthroplasty in dogs. *J Am Vet Med Assoc* 217:1010-1012, 2000.
118. Liska WD: Micro Total Hip Replacement for Dogs and Cats: Surgical Technique and Outcomes. *Vet Surg* 39:797-810, 2010.
119. Olmstead ML: Canine cemented total hip replacements: state of the art. *J Sm An Pract* 36:395-399, 1995.
120. Hayes GM, Ramirez J, Langley Hobbs SJ: Use of the Cumulative Summation Technique to Quantitatively Assess a Surgical Learning Curve: Canine Total Hip Replacement. *Vet Surg* 40:1-5, 2011.
121. Hach V: The HELICA-endoprosthesis—a new cementless hip endoprosthesis for dogs. *Vet Comp Orthop Traumatol* 23:297-305, 2010.
122. Guerrero TG, Montavon PM: Zurich cementless total hip replacement: retrospective evaluation of 2nd generation implants in 60 dogs. *Vet Surg* 38:70-80, 2009.
123. Budsberg SC, Chambers JN, Lue S, et al: Prospective evaluation of ground reaction forces in dogs undergoing unilateral total hip replacement. *Am J Vet Res* 57:1781-1785, 1996.
124. Bergh MS, Gilley RS, Shofer FS, et al: Complications and radiographic findings following cemented total hip replacement: a retrospective evaluation of 97 dogs. *Vet Comp Orthop Traumatol* 19:172-179, 2006.
125. Dyce J, Wisner ER, Wang Q, et al: Evaluation of risk factors for luxation after total hip replacement in dogs. *Vet Surg* 29:524-532, 2000.

126. Andrews CM, Liska WD, Roberts DJ: Sciatic neurapraxia as a complication in 1000 consecutive canine total hip replacements. *Vet Surg* 37:254-262, 2008.
127. Liska WD: Femur fractures associated with canine total hip replacement. *Vet Surg* 33:164-172, 2004.
128. Nelson LL, Dyce J, Shott S: Risk factors for ventral luxation in canine total hip replacement. *Vet Surg* 36:644-653, 2007.
129. Yates G, Wasik S, Edwards G: Femoral component failure in canine cemented total hip replacement: a report of two cases. *Aust Vet J* 88:225-230, 2010.
130. Terrell SP, Sundeep Chandra AM, Pablo LS, et al: Fatal intraoperative pulmonary fat embolism during cemented total hip arthroplasty in a dog. *J Am Anim Hosp Assoc* 40:345-348, 2004.
131. Schrader SC: Triple osteotomy of the pelvis as a treatment for canine hip dysplasia. *J Am Vet Med Assoc* 178:39-44, 1981.
132. Slocum B, Devine T: Pelvic osteotomy in the dog as treatment for hip dysplasia. *Semin Vet Med Surg (Small Anim)* 2:107-116, 1987.
133. Slocum B, Slocum TD: Pelvic osteotomy for axial rotation of the acetabular segment in dogs with hip dysplasia. *Vet Clin North Am Small Anim Pract* 22:645-682, 1992.
134. Slocum BD, T.: Pelvic osteotomy technique for axial rotation of the acetabular segment in dogs. *J Am Anim Hosp Assoc* 22:331-338, 1986.
135. Hara Y, Harada Y, Fujita Y, et al: Changes of hip joint congruity after triple pelvic osteotomy in the dog with hip dysplasia. *J Vet Med Sci* 64:933-936, 2002.
136. Hosgood G, Lewis DD: Retrospective evaluation of fixation complications of 49 pelvic osteotomies in 36 dogs. *J Sm An Pract* 34:123-130, 1993.
137. Rose BW, Novo RE, Olson EJ: Osteosarcoma at the site of a triple pelvic osteotomy in a dog. *J Am Anim Hosp Assoc* 41:327-331, 2005.
138. Dudley RM, Wilkens BE: Urethral obstruction as a complication of staged bilateral triple pelvic osteotomy. *J Am Anim Hosp Assoc* 40:162-164, 2004.
139. Papadopoulos G, Tommasini Degna M: Two cases of dysuria as a complication of single-session bilateral triple pelvic osteotomy. *J Small Anim Pract* 47:741-743, 2006.
140. Remedios A, Fries C: Implant complications of 20 triple pelvic osteotomies. *Vet Comp Orthop Traumatol* 6:202-207, 1993.
141. Koch DA, Hazewinkel HAW, al. e: Radiographic evaluation and comparison of plate fixation after triple pelvic osteotomy in 32 dogs with hip dysplasia. *Vet Comp Orthop Traumatol* 6:9-15, 1993.
142. Fitch R, Kerwin S, Hosgood G: Treatment of mechanically failed triple pelvic osteotomies in four dogs- part 2. *Vet Comp Orthop Traumatol* 15:172-176, 2002.
143. Simmons S, Johnson AL, Schaeffer DJ: Risk factors for screw migration after triple pelvic osteotomy. *J Am Anim Hosp Assoc* 37:269-273, 2001.
144. Whelan MF, McCarthy RJ, Boudrieau RJ, et al: Increased sacral screw purchase minimizes screw loosening in canine triple pelvic osteotomy. *Vet Surg* 33:609-614, 2004.
145. Fitch R, Kerwin S, Hosgood G: Radiographic evaluation and comparison of the triple pelvic osteotomy with and without ventral plate stabilization in forty dogs—part I. *Vet Comp Orthop Traumatol* 15:164-171, 2002.

146. Doornink MT, Nieves MA, Evans R: Evaluation of ilial screw loosening after triple pelvic osteotomy in dogs: 227 cases (1991-1999). *J Am Vet Med Assoc* 229:535-541, 2006.
147. Béosier Y, Daems R, Janssens L: Screw loosening six weeks after triple pelvic osteotomy. *Vet Comp Orthop Tramadol* 9:14-18, 2010.
148. Bogoni P, Rovesti GL: Early detection and treatment of screw loosening in triple pelvic osteotomy. *Vet Surg* 34:190-195, 2005.
149. Graehler RA, Weigel JP, Pardo AD: The effects of plate type, angle of ilial osteotomy, and degree of axial rotation on the structural anatomy of the pelvis. *Vet Surg* 23:13-20, 1994.
150. DeJardin LM, Perry RL, Arnoczky SP: The effect of triple pelvic osteotomy on the articular contact area of the hip joint in dysplastic dogs: an in vitro experimental study. *Vet Surg* 27:194-202, 1998.
151. Tomlinson JL, Cook JL: Effects of degree of acetabular rotation after triple pelvic osteotomy on the position of the femoral head in relationship to the acetabulum. *Vet Surg* 31:398-403, 2002.
152. Haudiquet PH, Guillon JF: Radiographic evaluation of double pelvic osteotomy versus triple pelvic osteotomy in the dog: an in vitro experimental study, Proceedings, Proceedings of the 13th ESVOT Congress, Munich, Germany, 10 September 2006, 2006 (available from
153. Vezzoni A: Double Pelvic Osteotomy Versus Triple Pelvic Osteotomy, Proceedings, American College of Veterinary Surgeons Symposium, Washington, D.C., October 8-10, 2009, 2009 (available from
154. Haudiquet PH, Guillon JF: Radiographic evaluation of double pelvic osteotomy versus triple pelvic osteotomy in the dog: an in vitro experimental study., Proceedings, ESVOT Congress, Munich, 2006 (available from
155. Wang SI, Mathews KG, Robertson ID, et al: The effects of patient positioning and slice selection on canine acetabular angle assessment with computed tomography. *Vet Radiol Ultrasoun* 46:39-43, 2005.
156. Johnson AL, Dunning, D.: *Atlas of Orthopedic Procedures for the Dog and Cat*. St. Louis, Elsevier Saunders, 2005.
157. Clark B, Wallace LJ, Pacchiana P: The effect of pelvic osteotomy plate type on axial rotation of the acetabular segment in the triple pelvic osteotomy. *Vet Comp Orthop Traumatol* 18:37-42, 2005.
158. Liao JJ, Lewis JW: A note on concordance correlation coefficient. *PDA J Pharm Sci Technol* 54:23-26, 2000.
159. Lin LI: A concordance correlation coefficient to evaluate reproducibility. *Biometrics* 45:255-268, 1989.
160. Vezzoni A: Double Pelvic Osteotomy Versus Triple Pelvic Osteotomy, Proceedings, American College of Veterinary Surgeons Symposium, Washington, D. C. , October 8-10, 2009, 2009 (available from
161. Fitch R, Hosgood G, Staatz A: Biomechanical evaluation of triple pelvic osteotomy with and without additional ventral plate stabilization. *Vet Comp Orthop Traumatol* 15:145-149, 2002.
162. Holton LL, Scott EM, Nolan A, et al: Comparison of three methods used for assessment of pain in dogs. *J Am Vet Med Assoc* 212:61-66, 1998.