

CALCANEUS FRACTURE

Background

1. Definition

- Hindfoot fracture, commonly associated with trauma

2. General Information

- Most inferior bone and largest tarsal bone
- Supports axial load from body weight¹
- 4 articular facets
 - One facet articulates with cuboid bone anteriorly
 - Superiorly articulates with talus, making the subtalar joint
 - Flexor hallucis longus tendon passes under sustentaculum tali (medial eminence)
 - Peroneus longus tendon passes under trochlear process (lateral tubercle)

Pathophysiology

1. Pathology of Disease

- Common causes of acute fracture include motor vehicle accidents and falls from over 6 foot height²
- Stress fractures occur with repetitive load to heel
 - Commonly posterior and inferior to posterior facet of subtalar joint³

2. Incidence, Prevalence

- 2% of all fractures; 60% of tarsal fractures¹
- Over 60% associated with fall from height; bilateral fractures in less than 10%¹
- In adults, 75% of calcaneus fractures intra-articular; 25% extra-articular¹
- Behind metatarsal, second most common foot stress fracture site⁴

3. Risk Factors

- Trauma, including motor vehicle accidents and falls with axial compression
- Osteoporosis
- Diabetes or other endocrine abnormality³

4. Morbidity / Mortality

- Often associated with high-energy heel impact; full trauma work-up warranted to look for other fractures of extremities and spine as well as solid organ damage⁵
- 10% of patients present with spinal compression injuries, commonly around thoracolumbar junction¹
- Soft-tissue involvement linked to poor functional outcomes¹
- Around 10% of patients develop compartment syndrome²
 - Long term effects include clawing of toes, stiffness, chronic pain, weakness and neurovascular injury

- Malunions resulting in widening of the heel or loss of height; complex regional pain syndromes and subtalar/calcaneocuboid arthritis may develop⁶
- Smoking and diabetes associated with surgical complications⁶

Diagnostics

1. History

- Traumatic forced dorsiflexion, motor vehicle accident, or fall from height
- Recent increase in walking activity seen before stress fractures³

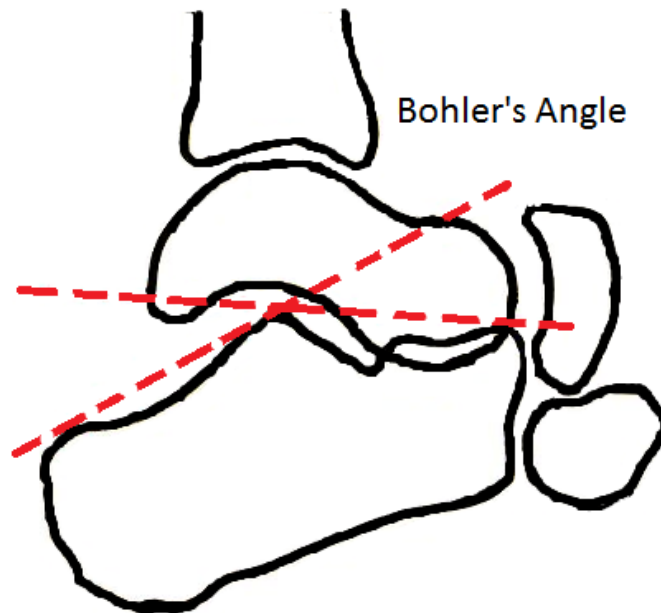
2. Physical Examination

- Pain most common presentation, especially when squeezing patients heel¹
- Diffuse pain poorly localizing to heel seen in intra-articular fractures³
- Point tenderness at fracture site in less severe or stress fractures
- Inability to bear weight or ambulate¹
- Limited eversion/inversion of foot¹
- Swelling, erythema and fracture blisters are signs of soft-tissue injury¹
- **Mondor sign**
 - Hematoma extending distally to sole of foot¹

3. Diagnostic imaging

- Conventional radiography used for initial evaluation¹
 - Anterior-posterior and oblique to assess calcaneocuboid joint
 - Axial (Harris view) of heel
 - Lateral views with dorsiflexion and internal rotation to visualize subtalar joint and posterior facet
- CT allows for better characterization of fracture lines and displaced fragments¹
- Bone scan or MRI often needed to diagnose stress fracture when plain radiography shows no fracture (SOR:C)⁴

- Lateral radiograph to assess **Bohler Angle**⁵



- Measure of the angle of intersection of lines drawn from anterior tuberosity to apex of posterior facet and from the posterior tuberosity to apex of posterior facet
 - Normal range: 25⁰-40⁰
 - <25⁰ associated with vertical compression fracture
- Intra-articular vs extra-articular based on subtalar joint involvement¹
- Extra-articular fractures¹
 - Type A – involve anterior process
 - Type B – midcalcaneus or body, includes trochlear process, sustentaculum tali, and lateral process
 - Type C – involve posterior calcaneus, includes posterior tuberosity and medial tubercle
- Sanders classification most commonly used for intra-articular fractures¹
 - Type I – non-displaced
 - Type II – displaced with posterior facet in 2 fragments
 - IIA – Lateral fracture line
 - IIB – Central fracture line
 - IIC – Medial fracture line
 - Type III – displaced with posterior facet having 3 major fragments
 - IIIAB – Lateral and central fracture lines
 - IIIAC – Lateral and medial fracture lines
 - IIIBC – Central and medial fracture lines
 - Type IV – comminuted

Differential Diagnosis

1. Key Differential Diagnoses⁴
 - Sever's Disease (in pediatric patient)
 - Ankle sprain
 - Talar fractures
 - Haglund deformity
 - Plantar fasciitis
 - Heel Pad Syndrome
 - Plantar wart
 - Tendinopathy
 - Retrocalcaneal bursitis
 - Tarsal Tunnel Syndrome
 - Heel spur
2. Extensive Differential Diagnoses⁴
 - Rheumatoid arthritis
 - Seronegative spondyloarthropathies
 - Diabetic Ulcers
 - Osteomyelitis
 - Lumbar radiculopathy
 - Neuroma
 - Ewing sarcoma

Therapeutics

1. Acute Treatment
 - Compression, ice, elevation and immobilization⁵
 - Extra-articular fractures can be managed non-operatively if no significant displacement or soft-tissue damage exists⁶
 - Early stress fracture treatment can range from decreasing activity to heel pad or walking boot⁴
2. Further Management (24 hrs)
 - Consider age, health, gender, mechanism of injury, soft tissue damage and Bohler angle measurement when determining treatment⁵
 - Studies show improved outcomes with open reduction and internal fixation (ORIF) in displaced intra-articular fractures⁵
 - Operative repair of displaced intra-articular fractures shows decreased time away from work and increased quality of life when compared to non-operative treatment⁷
 - Non-operative treatment may be preferred in older or high-risk individuals depending on extent of injury³

3. Long-Term Care
 - Monitor for compartment syndrome; multi-compartment fasciotomy if needed²
 - Healing should be monitored for malunion and functional and sensory deficits
 - Monitor surgically corrected fractures for evidence of infection

Follow-Up

1. Return to Office
 - Operative repair should occur within 3 weeks; before early consolidation, but after edema decreased as evidenced by return of normal skin wrinkles (typically 7-14 days)¹
2. Refer to Specialist
 - Podiatric or orthopedic consult for displaced fractures or extensive soft tissue damage

Prognosis

1. Outcome varies with severity of fracture and patient's comorbidities, ranging from return to normal function to disabling deformity
2. Displaced intra-articular fractures associated with poor clinical outcome despite various treatments; major socioeconomic impact from time off of work and away from recreation⁷

Patient Education

1. American College of Foot and Ankle Surgeons -
http://www.foothealthfacts.org/footankleinfo/fractures_calcaneus.htm

References

1. Badillo K, Pacheco JA, Padua SO, Gomez AA, Colon E, Vidal JA. Multidetector CT evaluation of calcaneal fractures. *Radiographics*. 2011 Jan-Feb;31(1):81-92.
2. Kalsi R, Dempsey A, Bunney EB. Compartment Syndrome of the Foot after Calcaneal Fracture. *Journal of Emergency Medicine*. Available online 14 December 2009, ISSN 0736-4679, 10.1016/j.jemermed.2009.08.059.
(<http://www.sciencedirect.com/science/article/pii/S0736467909008099>)
3. Thomas JL, Christensen JC, Kravitz SR, Mendicino RW, Schuberth JM, Vanore JV, Weil LS Sr, Zlotoff HJ, Bouche R, Baker J, American College of Foot and Ankle Surgeons heel pain committee. The diagnosis and treatment of heel pain: a clinical practice guideline-revision 2010. *Journal of Foot and Ankle Surgery*. 2010 May-Jun;49(3 Suppl):S1-19.
4. Tu P, Bytomski JR. Diagnosis of Heel Pain. *American Family Physician*. 2011 Oct 15;84(8):909-16.

5. Palmersheim K, Hines B, Olsen BL. Calcaneal fractures: update on current treatments. *Clinics in Podiatric Medicine and Surgery*. 2012 Apr;29(2):205-20.
6. Bernstein J, Ahn J. In brief: Fractures in brief: calcaneal fractures. *Clinical Orthopaedics and Related Research*. 2010 Dec;468(12):3432-4.
7. Brauer CA, Manns BJ, Ko M, Donaldson C, Buckley R. An economic evaluation of operative compared with nonoperative management of displaced intra-articular calcaneal fractures. *Journal of Bone and Joint Surgery. American Volume*. 2005 Dec;87(12):2741-9

**Authors: Erik R. Clauson, MSIII, Philadelphia College of Osteopathic Medicine,
& James W. Haynes, MD, University of Tennessee Chattanooga Unit FPR**

**Editor: Robert Marshall, MD, MPH, MISM, CMIO,
Madigan Army Medical Center, Tacoma, WA**