VETERINARY MEDICAL REVIEW

Congenital heart disease

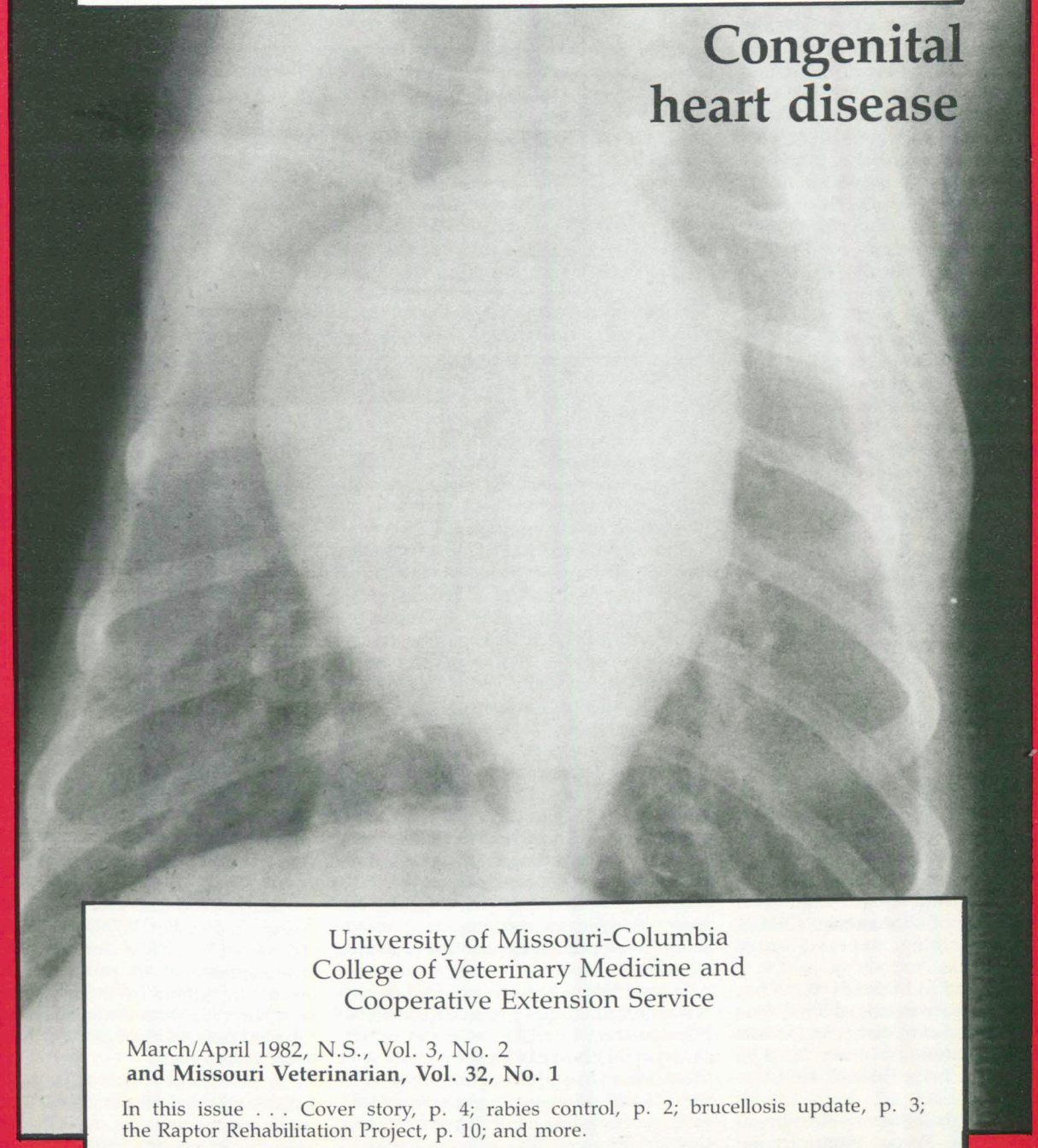

University of Missouri-Columbia
College of Veterinary Medicine and
Cooperative Extension Service

March/April 1982, N.S., Vol. 3, No. 2
and Missouri Veterinarian, Vol. 32, No. 1

In this issue . . . Cover story, p. 4; rabies control, p. 2; brucellosis update, p. 3; the Raptor Rehabilitation Project, p. 10; and more.

Rabies

Public awareness is the key to control.

Donald C. Blenden, D.V.M., M.S.
Department of Veterinary Microbiology

It's rabies season again. As surely as the calendar heralds the approach of warmer weather, so too do health officials begin to sound the rabies warnings.

Missouri is in the midst of a rabies epidemic that may last several more years. In 1979, the number of confirmed rabies cases in Missouri increased threefold over 1978. The 1980 cases numbered 379; in 1981, 243. In the first three months of 1982, 41 cases were confirmed. Moniteau County already has been placed under quarantine this year, a county that had reported no rabies activity since the present epidemic began in 1978.

In July 1981, an Oklahoma City man died of rabies—the first human death from rabies recorded in nearly two years. That was followed the next month by another death in Tucson, Arizona. A Tucson man had vaccinated his dog himself. The dog later contracted the virus and bit his master; both died.

Local veterinarians often are called upon by citizen groups to discuss the dangers of rabies. Missouri's precarious position with the disease could make the demand for public education even greater this year. Practitioners should not hesitate to speak out on the dangers of rabies and the need for control. The following "fact sheet" highlights important issues in rabies control, and may be useful in public presentations.

Facts About Rabies in Missouri

Rabies is currently a skunk problem. There is little incidence in foxes and raccoons.

The dog and cat are the animals interfacing skunks, wildlife, and the human, and the only animals transmitting rabies over which we have any control.

The cardinal rules of rabies control are a) control of stray and undesired animals, b) immunization of all domestic animals capable of transmitting, and c) control of wildlife rabies.

Nationwide and in Missouri, there is a tremendous increase in animal bites. One percent of hospital emergency room visits are for animal bites. Of those, 80 to 90 percent are dog bites (JAMA, Nov. 21, 1980).

Each bite needs rabies evaluation at considerable cost. Proper immunization history is a vital portion.

The highest risk in animal bites (and rabies) is the male child, then female child, then occupational groups.

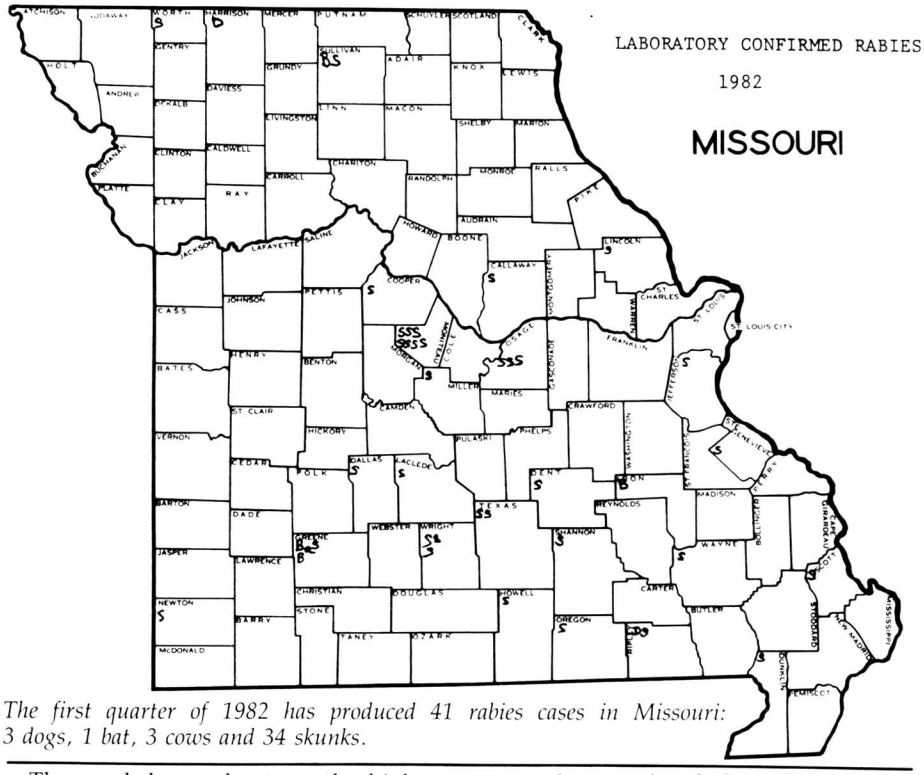

The first quarter of 1982 has produced 41 rabies cases in Missouri: 3 dogs, 1 bat, 3 cows and 34 skunks.

The rural dog and cat are the highest risk, because of a) wildlife contact potential and b) the lack of compulsory immunization now present in many cities.

Studies on stray dogs show 70 percent to be previously owned; compulsory immunization therefore will result in an increase in rabies immunity in strays.

There are 30,000-50,000 persons treated annually for rabies exposures in the United States (based on vaccine sales). There are 35 states in which rabies is important; therefore, 850-1,450 Missourians receive treatment per year. At $500 per treatment, Missourians annually spend $425,000 to $725,000 for this purpose. This is under normal, routine circumstances and only covers vaccine costs.

Missouri has never had an adequate rabies control law. In response to a large epidemic in dogs in the 1950-53 period, a law was passed which gave state government some quarantine ability and required immunization or confinement of dogs *under a quarantine only.* In 1955, the law was rescinded in response to pressure from a segment of the fox-hunting population.

Since 1955, when the rabies law was rescinded, there have been 21,000-36,000 Missourians treated for rabies exposures, at an average cost of $500 for vaccine only. Thus, Missourians have spent $10,625,000-$18,125,000 on post-exposure treatment. With proper rabies control and education, this figure would have been markedly less.

Since 1955 in Missouri, there have been 814 officially recorded cases of rabies in dogs. With an estimate of eight persons exposed to each of these dogs, 6,512 persons have received treatment at a total cost of $3,256,000; all the result of dog rabies and partly due to the rescinding of the 1955 law. At 5-25 injections per person, 6,512 people received 32,500-162,500 injections. (The new vaccine now calls for only six injections, but the cost is about the same.)

Since 1955, there have been 319 officially recorded cases of rabies in cats. With an estimated two persons exposed to each, 638 persons have received 3,100-16,000 injections at a cost of $319,000.

During an epidemic period (now), it is safe to estimate 2,000 Missourians are taking treatment annually; at $500 per treatment, that equals $1 million. Actual costs are HDC vaccine, 5 doses at $50 each totaling $250 plus globulin at $200 for an average dose, which equals $450. This covers vaccine and globulin only and not its administration, consultation costs, transportation and time lost from work.

During the current epidemic period (since September 1978), there have been 88 cases of rabies in dogs and cats. With the estimate of six post-exposure treatments resulting from each case, there have been 528 Missourians take treatment at $500 each, or $264,000 for dog and cat exposures only.

In St. Charles County, one dog with rabies exposed 88 persons, all of whom were treated at a cost of $500 each. Thus, $44,000 in vaccine costs alone accumulated as a result of one dog. An estimated 300 to 400 persons were evaluated for

Continued on Page 3

BRUCELLOSIS UPDATE

Missouri's infection rate continues to decline.

The unofficial report card is out on Missouri's brucellosis eradication program: Class B status.

"It's not official yet, but the infection rate is well below 1.5 percent," says Acting State Veterinarian James McGinnis.

New state classifications that went into effect January 1 divided the country into four categories of brucellosis infection: Free, Class A, Class B, and Class C.

Brucellosis-free states must remain so for at least 12 months, with a Market Cattle Identification rate of 0.05 percent or less. Class A states must not have an infection rate of more than 0.25 percent. The Class A MCI reactor rate must be below 0.1 percent.

In Class B, where Missouri falls, the infection rate cannot exceed 1.5 percent of the state's herds. Missouri's 220 infected herds fall within that limit. The MCI reactor rate in a B state cannot exceed 0.30 percent; if it does, the state drops to C status. That market infection rate limit will drop to 0.20 percent on January 1, 1983. MCI sampling rates in Class B or C states must be at least 95 percent, with at least 80 percent of the MCI reactors traced back to herd of origin and investigated or tested within 30 days. Adjacent and epidemiologically traced herds must have an action plan in effect within 45 days of disclosure.

The U.S. Department of Agriculture requires all states to conduct Brucellosis Ring Tests at least four times a year. Every herd must be included on at least three consecutive BRT rounds.

As long as Missouri remains a B state, all breeding cattle moved interstate must undergo pre-movement and post-movement tests. Pre-movement tests are required on breeding cattle moved within Missouri; a post-movement test is recommended.

Missouri probably will remain in the B class for some time. "It's wishful thinking to say otherwise," Dr. McGinnis says. "But I hope we can achieve A status in 1 to 2 years. It all depends on the numbers."

Dr. McGinnis says budget cuts make it unlikely there will be another state-funded brucellosis vaccination program to follow the 1981 program. Although the state still is providing Strain 19 vaccine free to veterinarians, the veterinarian's charges must be borne by the livestock producer this year.

The number of vaccinations is increasing tremendously. USDA figures show that 182,500 head of Missouri cattle were vaccinated against brucellosis in fiscal year 1981 (October 1980 to September 1981). Since October of 1982, 219,193 vaccinations have been given.

Brucellosis Eradication

Percent of Total Reactor Herds Found

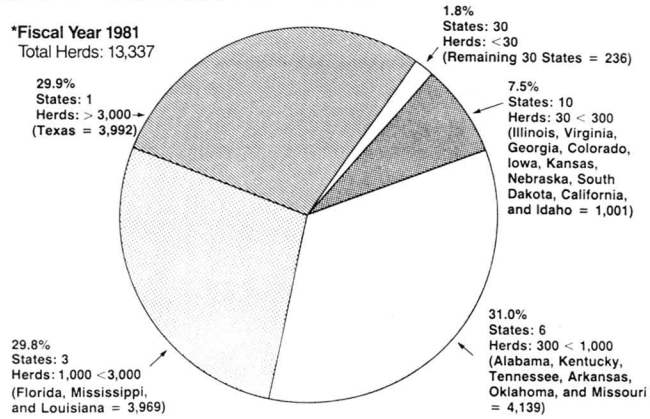

*Estimated.

Brucellosis Eradication

Calves Vaccinated

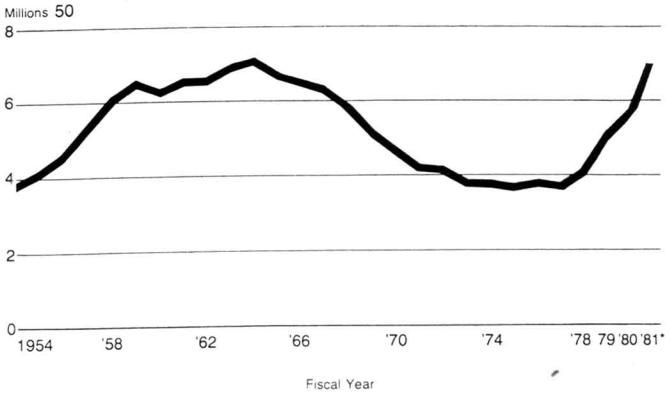

*Estimated.

Illustrations courtesy of Livestock Conservation Institute

Rabies

From Page 2

exposure with enormous medical and administrative costs.

Those bitten and not treated have enormous hidden costs—medical costs, transportation to hospitals, time off work are dollar costs. Anxiety is another enormous problem. I personally have 10 to 45 telephone calls per week about animal bites and rabies exposures, 75 percent from Missouri citizens, 25 percent from outside Missouri.

There are no more adverse effects from rabies vaccine than from any other vaccine. The oft-rumored loss of smell in hunting dogs has no basis or proof.

Historically in Missouri (for 30-plus years of rabies reporting), the spring season is the heaviest, followed by a slow decline to the lows in October-November, followed by a sharp rise in the spring. There is no reason to suspect a change in that pattern, meaning that the spring increase is here.

Owner versus veterinary vaccination becomes an issue when a third party gets involved. When a person is bitten, assessing the risk of the bite and the probability of rabies exposure depends on whether the dog was immunized and how reliably. The veterinarian is legally empowered and responsible for appropriate administration. In assessing the credibility of the immunization, the following questions are pertinent:

- Was the vaccine actually given?
- Was the vaccine given in the right location?
- Did any antiseptic get mixed with the vaccine?
- Was an abcess produced?
- Had the vaccine been properly refrigerated?
- Was the vaccine used within its expiration date?
- Was the vaccine over-diluted with water to get two for one?
- Was the vaccine properly mixed?
- Was the animal in a good state of health when the vaccine was administered, or was it compromised due to poor health?

Practitioners with additional questions may contact Dr. Donald Blenden at the College's Rabies Research Laboratory, (314) 882-3083.

Congenital heart disease

Radiography provides a specific diagnosis to aid in advising clients with problem pets.

Everett Aronson, D.V.M.
Dudley McCaw, D.V.M.
Department of Veterinary Medicine & Surgery

Congenital cardiac anomalies must be recognized by veterinarians in order to advise clients about possible problems that can arise in their pets. This is especially true for pets purchased with a guarantee.

Auscultation generally reveals a murmur in puppies with congenital heart diseases. In order to provide the pet owner with a specific diagnosis, radiography—and many times contrast radiography—is necessary. Most radiographic procedures can be performed without costly specialized equipment. In the next few issues of *Veterinary Medical Review*, we hope to provide the information and techniques required to diagnose the more common congenital heart diseases.

History:

The animals usually are presented with no history of heart disease. Congenital anomalies usually are diagnosed before the animal is clinically ill; sometimes, however, the animal has not been presented for examination and preventative care.

The history in congenital heart disease that has progressed to the clinical stage is similar to heart diseases from other causes. Owners will comment about cough, reduced exercise tolerance, or ascites, depending upon the anomaly.

Physical examination:

The most critical parts of the physical examination are auscultation, the pulse character and the appearance of the mucous membranes. Auscultation is extremely important and can be very rewarding if analyzed closely. The normal first heart sound is closing of the atrial-ventricular valves, while the normal second heart sound is closing of the pulmonic and aortic valves. Blood normally flows through the heart with a laminar flow and therefore produces no audible sounds. When that flow is interrupted, it produces turbulence and a murmur may be heard. Leakage of a valve or a congenital leakage of the vessels or heart tissue will produce a murmur. Constriction or a stenotic area in a vessel also will interrupt the normal smooth flow of blood and produce a murmur.

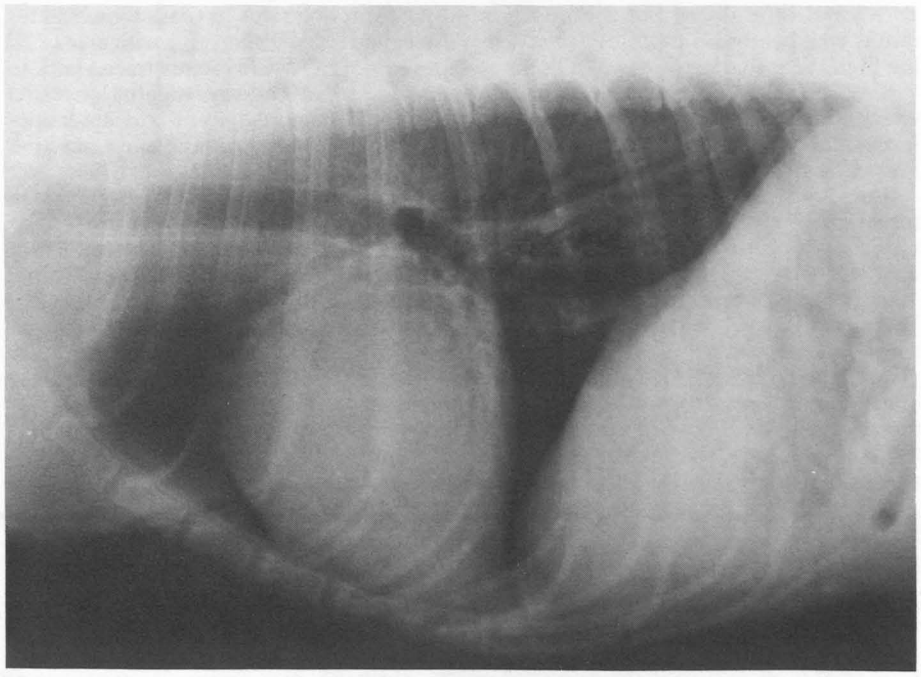

Radiograph 1: Normal lateral and ventrodorsal radiographs of the thorax.

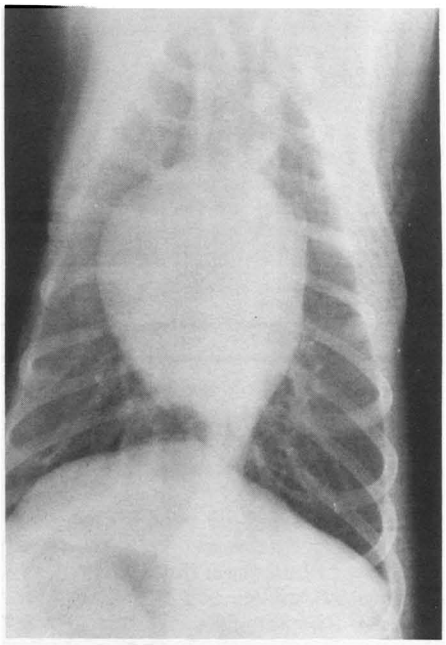

A murmur is described according to the part of the cardiac cycle in which it occurs and the type of sound produced. The stage of the cardiac cycle may be diastole, systole, or both. The closing of the atrioventricular valves (the first heart sound) is the end of diastole and the beginning of systole; therefore, a murmur occurring at this time would be systolic. The closing of the aortic and pulmonic valves (second heart sound) is the end of systole and beginning of diastole; a murmur auscultated at this time would be termed diastolic.

The types of sound refer to the intensity of the murmur. Increasing intensity is called crescendo, decreasing intensity decrescendo, and near-same intensity holo. These terms then are combined with the stage of the cardiac cycle giving us descriptions such as holosystolic, crescendo-decrescendo systolic, etc.

The location in which the murmur best can be auscultated also is important. Most murmurs will radiate throughout the chest but can be auscultated best at a specific point. This can be helpful in diagnosing heart diseases.

Pulse is another parameter that can be examined easily. This is especially useful when the pulse is palpated while auscultating the heart sounds. The pulse we perceive is the difference between the systolic blood pressure and the diastolic pressure. Wide differences in these two pressures are perceived as a strong pulse; conversely, systolic and diastolic pressures that are similar are felt as a weak pulse.

Mucous membranes also should be examined for cyanosis. Since certain anomalies can cause oxygenated blood to go anteriorly and unoxygenated blood posteriorly, it is important to look at mucous membranes at both ends of the animal.

Electrocardiogram:

In congenital heart disease, this usually does not give us any additional information. Parameters such as chamber enlargement can be detected radiographically; however, an ECG can help confirm a diagnosis.

Clinical Pathology:

In conditions that produce right-to-left shunts, unoxygenated blood will be circulated through to peripheral circulation. Oxygen saturation will be decreased if measured. In most cases, the kidney will react to this low-oxygen tension by increasing erythropoietin output and thus increasing the packed cell volume.

Radiography:

It is imperative to have good radiographic technique before a thoracic radiograph can be evaluated properly for signs of heart disease. Proper technique includes exposure factors and positioning.

Accurate evaluation of the size and shape of the cardiac silhouette only can be made on a well-positioned radiograph. On a lateral radiograph, the entire thorax should be visible from the thoracic inlet to the diaphragm and from the sternabra to the thoracic vertebral column. The muscles and bones of the front limbs should be pulled forward so that they don't obscure the cranial lung lobes. The ribs as they rise from the vertebral column and their costal chondral junctions should be at the same level. On the ventrodorsal or dorsoventral injection, the vertebral column should be superimposed over the sternabra. (See Radiograph 1).

Proper technique is especially important in evaluating the pulmonary vasculature. On a lateral radiograph, the cranial thoracic vertebral bodies should be underexposed and the ribs should just be visible over the cardiac silhouette. On the dorsoventral or ventrodorsal radiograph, the vertebral column should be faintly visible through the cardiac silhouette. Because the heart increases in size both absolutely and relatively to thoracic size during expiration, all radiographs should be exposed at peak inspiration with short exposure times of at least 1/30 second, to obtain a valid representation of the true cardiac size.

It is important to remember that the shape of the cardiac silhouette differs in appearance on the dorsoventral and ventrodorsal projections. On the dorsoventral projection, the heart appears more upright and rounder while on the ventrodorsal projection the heart appears more elongated and tends to accentuate the pulmonary artery bulge. It is important, therefore, to be consistent when radiographing the thorax to evaluate the cardiac silhouette and take either ventrodorsal or dorsoventral projections exclusively. This will help minimize the possibility of arriving at an erroneous diagnosis based on an unfamiliar appearance of the cardiac silhouette. (See Radiograph 2.)

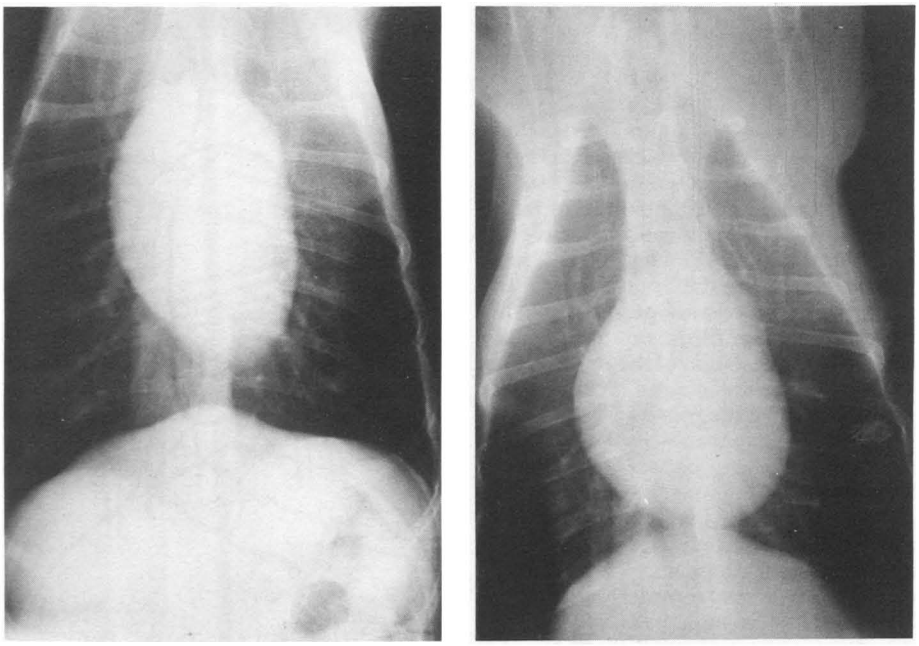

Radiograph 2: Ventrodorsal projection, left (note elongated cardiac silhouette). Dorsoventral projection, right (cardiac silhouette appears rounder and more upright).

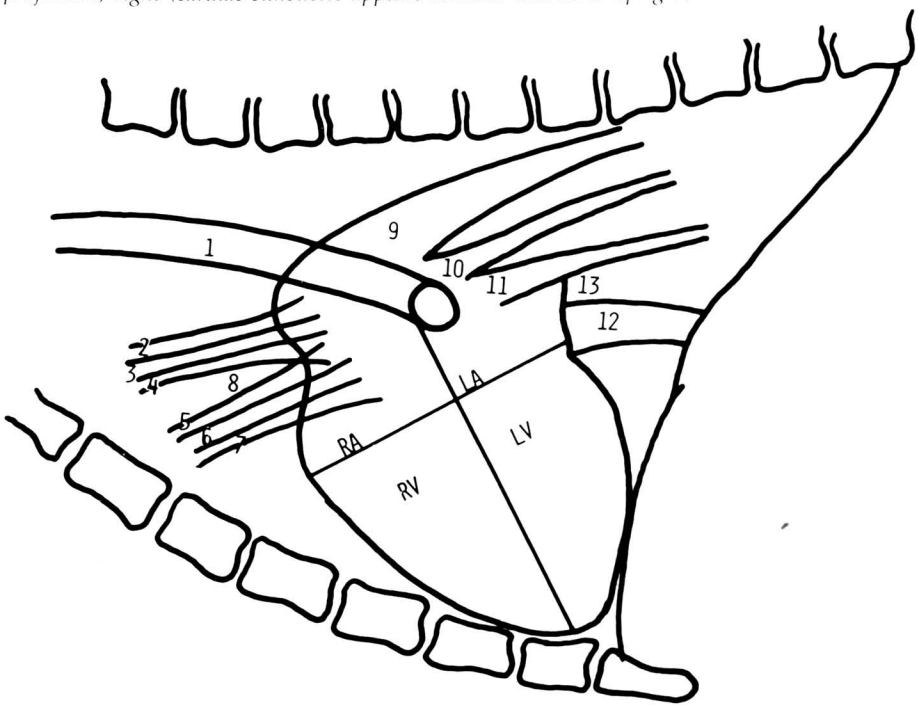

Figure 1: 1. Trachea. 2, 3, 4. Artery, bronchus, vein to left cranial lung lobe. 5, 6, 7. Artery, bronchus, vein to right cranial lung lobe. 8. Cranial waist. 9. Descending aorta. 10, 11. Pulmonary vessels to caudal lung lobes. 12. Caudal vena cava. 13. Caudal waist. (RA = Right Atrium; RV = Right Ventricle; LA = Left Atrium; LV = Left Ventricle)

When evaluating an animal for congenital cardiac disease, the radiographic findings must be correlated with the findings of the physical exam, history, and ECG.

The plain film radiographs by them-

Continued on Page 6

Heart

From Page 5

selves seldom are pathognomonic for specific congenital cardiac disease. There will be some cases when it will be necessary to perform non-selective angiocardiography or do a cardiac catheterization to arrive at a definitive diagnosis. However, by systematically evaluating the appearance of the cardiac silhouette and pulmonary vasculature on plain films, one can classify the disease; correlation of the radiographic findings with the clinical findings will offer a tentative diagnosis.

The normal appearance of the cardiac silhouette will vary between the breeds. Deep-chested dogs such as Irish setters and Afghan hounds will have hearts that are more upright and narrower than barrel-chested dogs such as bulldogs whose hearts are rounder and wider. These differences must be taken into consideration while evaluating these dogs for heart enlargement.

On the lateral view, the trachea is the first structure that should be evaluated in relation to the cardiac silhouette. The long axis of the trachea and the thoracic spine form an angle at the thoracic inlet and diverge caudally. The terminal trachea tends to bend slightly ventrally as it bifurcates into the main bronchi and forms the carina. The carina should be at the height of two-thirds the distance between the sternum and the thoracic vertebra.

The cranial caudal dimension of the heart should be between 2½ and 3½ intercostal spaces, depending on the breed. There should be a slight indentation of the cardiac silhouette at its dorsal cranial margin where it intersects with the ventral margin of the anterior vena cava and forms the cranial waist. The ventral aspect of the cranial cardiac silhouette should be in contact with one or two sternabra. The caudal margin of the cardiac silhouette, which represents the borders of the left atrium and ventricle, should be slightly rounded and form a slight indentation between the left atrium and ventricle known as the caudal waist. A line drawn from the carina to the apex divides the heart into two parts. The cranial area, which is approximately 60 percent of the cardiac silhouette, represents the right atrium and right ventricle. The caudal 40 percent of the cardiac silhouette represents the left atrium and left ventricle (Figure 1).

On the ventrodorsal projection, the right and left borders of the cardiac silhouette should be equidistant from the body walls. The cardiac apex usually lies to the left of midline. Normally the aortic arch and main pulmonary artery that lie in the left cranial aspect of cardiac silhouette are superimposed over the heart and are not visualized as separate structures (Figure 2).

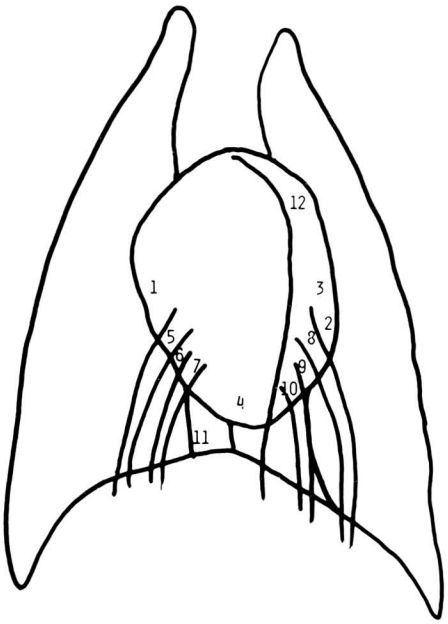

Figure 2: 1. Right ventricular border. 2. Left ventricular border. 3. Left auricle. 4. Left atrium. 5, 6, 7. Artery brochus and vein to right caudal lung lobe. 8, 9, 10. Artery, bronchus and vein to left caudal lung lobe. 11. Posterior vena cava. 12. Descending aorta.

After evaluating the cardiac silhouette, go on to the pulmonary vasculature. On the lateral projection, the vessels to the left and right cranial lung lobes should be examined. Normally the artery, bronchus, and vein to the lung lobe form a triad of structures with the artery dorsal to the air-filled bronchus with the vein ventral.

Peripherally, the artery, bronchus, and vein to the left lung lobe usually are dorsal to the artery, bronchus and vein of the right lung lobe. Vessel size is an important indicator of the type of disease that may be present. The artery and vein (to the same lung lobe) should be equal in size and as they cross the fourth rib should be no larger than the upper third of the third rib and no smaller than one-third the size of the third rib. On the ventrodorsal projection, the vessels to the caudal lung lobes as they cross the diaphragm should be between .75 and 1.5 times the size of the nearest rib.

Cardiomegaly is the most common sign of congenital heart disease. It is important to determine if the heart enlargement is due primarily to right-sided enlargement, left-sided enlargement or bilateral enlargement.

Radiographic signs of right ventricular enlargement on the lateral projection include loss of the cranial waist, increase in the cranial caudal dimension of the heart (greater than three intercostal spaces for the average dog), increase sternal contact and elevation of the cardiac apex off the sternum. If a line were drawn from the carina to the apex, the cranial area of the heart would be greater than 60 percent (Figure 3).

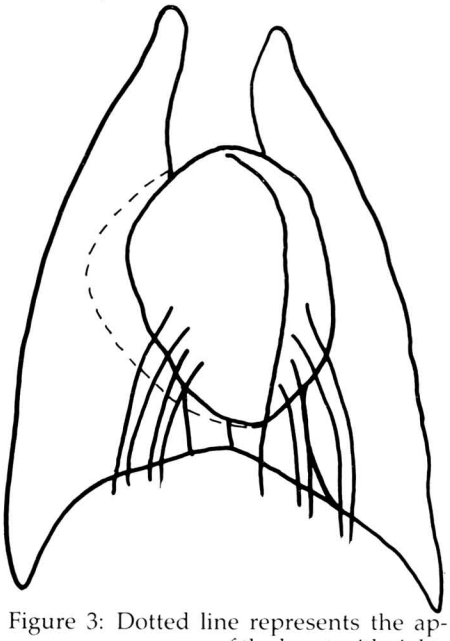

Figure 3: Dotted line represents the appearance of the heart with right-sided heart enlargement.

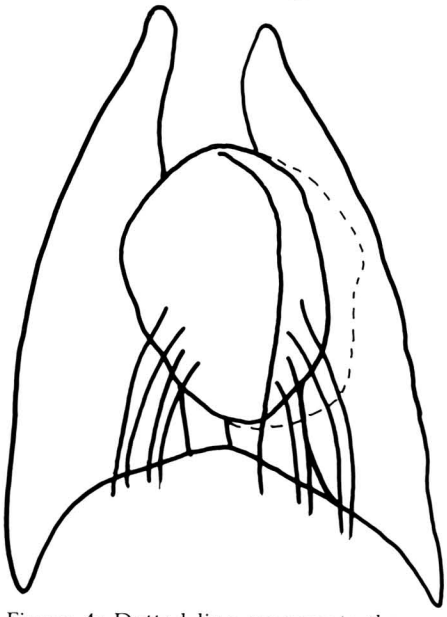

Figure 4: Dotted line represents the appearance of the heart with right-sided heart enlargement.

On the ventrodorsal projection, the right ventricular border is closer to the right body wall than is the left border of the heart to the left body wall. There often is a characteristic inverted "D" shape to the right ventricular border of the heart (Figure 4). Radiographic signs of left-sided enlargement on the lateral projection include elevation of the carina, loss of the caudal waist, a straighter and more perpendicular caudal cardiac border, separa-

tion of the main stem bronchi, compression of the bronchus to the left caudal lung lobe and an increased distance between the carina and the dorsal border of the posterior vena cava (Figure 5).

On the ventrodorsal projection, the left ventricular border of the heart is elongated and more convex. The left ventricular border is closer to the left body wall. Left atrial enlargement is demonstrated by separation of the main stem bronchi to the caudal lung lobes and, if the atrial enlargement is severe enough, there may be bulging of the left auricular appendage midway along the left ventricular border (Figure 6). Enlargement of the aorta and main pulmonary artery segments may appear on the lateral projection as soft tissue dense structures obscuring the cranial waist. On the ventrodorsal projection, they may appear as soft tissue bulges on the left cranial aspect of the cardiac silhouette.

The changes in the cardiac silhouette and the appearance of the pulmonary vasculature together can classify the type of congenital heart disease present and lead to a reliable tentative diagnosis. The common congenital heart diseases can be categorized according to the size of the pulmonary vessels. When the arteries and veins are both enlarged, it is classified as a hypervascular lung field and is indicative of a cardiac lesion with a left-to-right shunt such as patent ductus arteriosus, or ventricular septal defect. The pulmonary vasculature is considered hypovascular when the vessels are smaller than normal. This suggests a cardiac lesion with a right-to-left shunt such as tetralogy of fallot. Congenital heart diseases such as pulmonic stenosis or aortic stenosis have enlarged hearts but generally have normal-sized pulmonary vasculature (Figure 7). After classifying the cardiac anomaly according to the pulmonary vasculature and correlating this with the changes present in the cardiac silhouette, a tentative radiographic diagnosis can be obtained. For example, patent ductus arteriosus and ventricular septal defect both have hypervascular lung fields and both demonstrate right ventricular enlargement and left atrial enlargement, and both may have a pulmonary artery bulge. However a patent ductus arteriosus also usually will demonstrate left ventricular enlargement and an aortic aneurysmic widening and bulge of the left auricular appendage on the ventrodorsal radiograph. Young animals with congenital aortic stenosis and pulmonic stenosis normally will present with normovascular lung fields. They both will demonstrate a loss of the cranial waist on the lateral projection but pulmonic stenosis will show right ventricular enlargement and a pulmonary artery bulge on the ventrodorsal projection while aortic stenosis will show left ventricular enlargement and an aortic bulge on the ventrodorsal projection. Another example is the difference between tetralogy of fallot and ventricular septal defect. Both present with right ventricular enlargement; however, tetralogy of fallot will have a hypovascular lung field and ventricular septal defect will have a hypervascular lung field.

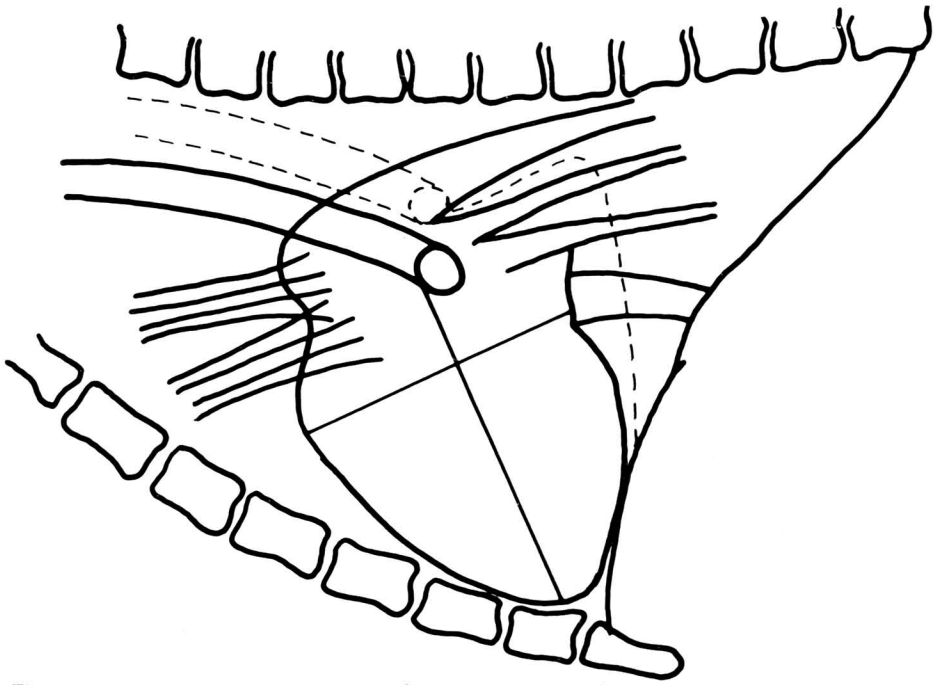

Figure 5: Dotted lines represent the appearance of the trachea and the heart with left-sided heart enlargement.

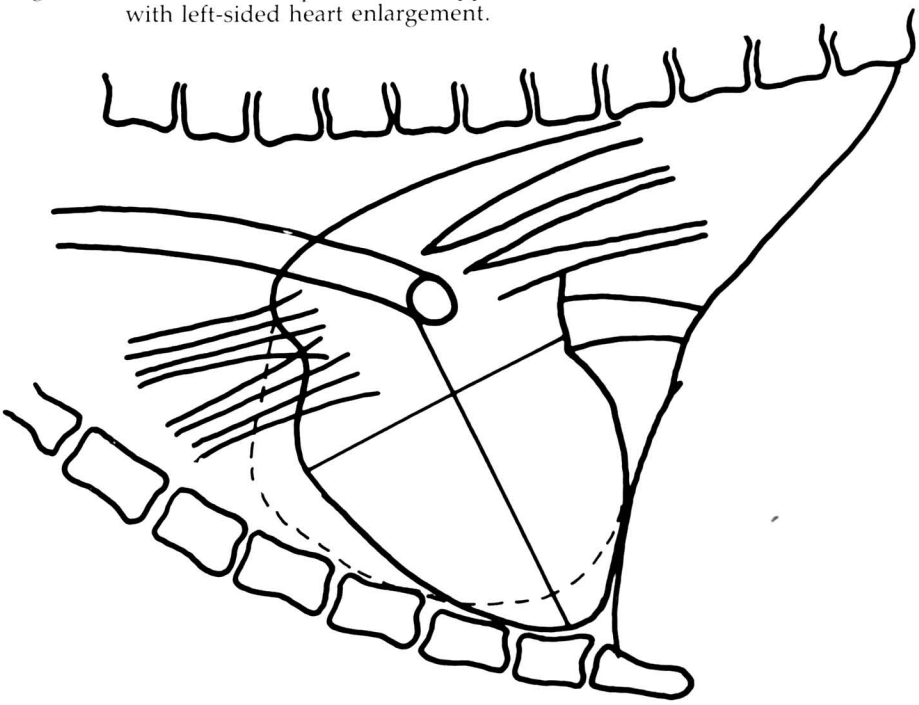

Figure 6: Dotted line represents the appearance of the heart with left-sided heart enlargement.

Unfortunately, plain film radiographs of the thorax do not always allow a definitive clinical diagnosis. For example, the radiographic changes of the cardiac silhouette may not be advanced sufficiently to be visualized, or the changes in the pulmonary vasculature may be only minimal. If a congenital disease is not recognized early, secondary changes in the heart may result and cause unusual radiographic findings. A young animal with an uncomplicated aortic stenosis may go undiagnosed until three years of age when it finally becomes symptomatic. At this time, he may present with the usual radio-

Continued on Page 8

1981 AAHA programs now in library

Slide-tape programs that were presented at the 1981 annual meeting of the American Animal Hospital Association are now available for autotutorial study in the College's Veterinary Medical Library.

The set of 17 continuing education presentations was donated to the College by Pitman-Moore Inc. Since 1971, Pitman-Moore has reproduced the AAHA presentations and provided them to veterinary schools, free of charge.

Topics in the 1981 set include:

"Epidural Anesthesia in the Dog" by Dr. R. L. Bradley of New York's Animal Medical Center.

"Corona, Parvo and Rota Viruses in the Dog" by Dr. Robert Ridgway and Dr. Leonard Binn, both of Walter Reed Army Medical Center.

"Anterior Cruciate Repair—Fascial Strip Over-the-Top Method" by Dr. R. L. Leighton of the University of California-Davis.

"Initial and Continued Management of Diabetes Mellitus" by Dr. C. B. Chastain of the University of Missouri (then at Iowa State University).

"Ethylene Glycol Poisoning in Small Animals" by Dr. M. A. Thrall and Dr. G. F. Grauer, both of Colorado State University.

"Clinicopathologic Evaluation of Animals with Pleural Effusions" by Dr. M. A. Thrall.

"Management of the Chronic Renal Failure Patient" by Dr. G. F. Grauer.

"Toxoplasmosis" by Dr. B. C. Ward and Dr. J. K. Frenkel, both of Mississippi State University.

"Medial Transfer of the Deep Gluteal Muscle in Excision Anthroplasty" by Dr. R. Dueland of the University of Wisconsin.

"Full Cylinder Cortical Bone Grafts in the Dog" by Dr. J. W. Alexander of the University of Tennessee.

"Differential Diagnosis of Pigmented Ocular Lesions in the Dog and Cat" by Dr. R. L. Peiffer Jr. of the University of North Carolina.

"Ophthalmoscopic Interpretation of Fundic Lesions in Animals" by Dr. G. L. Blanchard of Michigan State University.

"Use of Kirschner Apparatus in Long Bone Fractures" by Dr. H. W. Boothe Jr. and Dr. C. H. Tangner Jr., both of Texas A&M University.

"Diagnosis and Treatment of Congenital Portal Caval Shunts" by Dr. D. C. Twedt of Colorado State University.

"Anatomy of the Canine Stifle" by Dr. S. J. Updike of Ohio State University.

"Examination and Simplified Biopsy Techniques of the Colon" by Dr. W. E. Crenshaw of Texas A&M University.

"Surgical Management of Gastric Dilatation Volvulus" by Dr. R. W. Moore and Dr. W. E. Wingfield, both of Colorado State University.

Heart

From Page 7

graphic signs of aortic stenosis plus an enlarged left atrium and venous engorgement due to secondary mitral insufficiency and early left heart failure.

In these cases, when the diagnosis cannot be made from the plain films, contrast radiography in the form of nonselective venous angiocardiography or cardiac catheterization should be performed. A method on non-selective angiocardiography that can be performed by the general practitioner will be described in a later article.

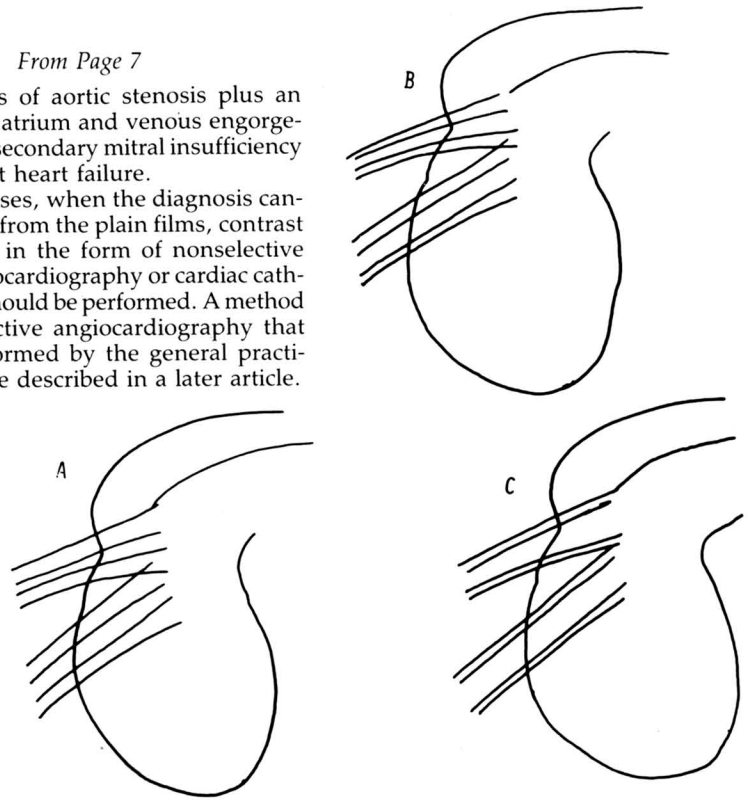

Figure 7: A = Hypervascular lung field. B = Normovascular lung field. C = Hypovascular lung field.

Datebook

June 10. SCAVMA speaker: Dr. Bill Kay, Director of New York City's Animal Medical Center, will speak on "The Animal Medical Center and Post-Graduate Opportunities," 8 p.m. in the College's Teaching Hospital Auditorium.

June 28-30. 8th Symposium on Veterinary Medical Education, University of Tennessee, Knoxville.

July 19-22. AVMA convention, Salt Lake City, Utah. The College will have an alumni reception and luncheon. Check your program for details.

October 10-11. 58th Annual Conference for Missouri Veterinarians, at the College and Columbia's Ramada Inn. Class reunions for 1957, 1967 and 1977 will precede the conference on October 9 at the Ramada Inn.

October 16. Alumni Day at the College. Events will include the Missouri-Iowa State football game. Morning festivities will get under way at the University's Alumni Center. Watch this space for details.

Dr. Bierschwal receives Alumni Association's most prestigious award

The University Alumni Association has honored the College's Dr. C. J. Bierschwal with its 1982 Distinguished Faculty Award. The annual award is the association's most prestigious, honoring Dr. Bierschwal's outstanding contributions to the University, particularly his work with students.

Dr. Bierschwal, a professor of veterinary medicine and surgery, has taught theriogenology at the College since 1951. He has twice won the Norden Teaching Award at the College, and received a Faculty-Alumni Award in 1970. The Missouri Beef Cattle Improvement Association honored him in 1979 as Outstanding State Extension Specialist.

A graduate of Iowa State University's College of Veterinary Medicine, Dr. Bierschwal holds a master's degree from the University and is a Diplomate of the American College of Theriogenologists.

Dr. Garner receives Heart Association grant

Interim Associate Dean Harold Garner has received a $15,260 grant from the Missouri affiliate of the American Heart Association to study hemodynamic response to myocardial ischemia in ponies.

Dr. Garner teaches equine medicine and surgery in the College's veterinary medicine and surgery department.

Dean's Corner

We will be graduating our 33rd class May 15, 1982. This class, with 74 students, is the largest graduating class to date.

There are 51 male and 23 female students.

The class entered with a G.P.A. of 3.60 and, at the time of this writing, has a G.P.A. of 3.07.

There have been many changes in the College of Veterinary Medicine during those 33 years. We evolved from a Department of Veterinary Science in the College of Agriculture to a School of Veterinary Medicine, and then to the present, College of Veterinary Medicine.

The physical plant has enlarged from two buildings, Connaway Hall and the Clinic Building, to the Teaching Hospital, Veterinary Medicine Building, Equine Center and Diagnostic Laboratory. These buildings house for the most part the educational facilities of our College. Of course, we are spread campus-wide in our research endeavors. We have just been given permission to build an isolation hospital at the Equine Center.

The faculty, staff and student body has increased in size along with the physical plant, the peak years for total number of faculty and staff probably being 1977 to 1979.

Our peak period for student applications was 1973 to 1976. The applicant pool is now somewhat less than those years. The quality of the accepted student, however, has remained at a high level.

Budgetary problems began to arise on the campus several years ago. This year, the state funds of the College were cut $497,450. This will force the College to lose 10 faculty, seven resident, and 10 staff positions. Fortunately, several open positions at this time have reduced the actual number of people to be terminated.

The College may not be able to maintain its current full accreditation it received in 1977. At that time, with faculty numbers being at a peak, the Council on Education warned that "faculty members are small and in several areas back-up strength should be provided."

What will the future hold? I really don't know. I hope we have reached the limit of our budget cuts.

The alumni of the College have given us strong support throughout the state and the nation. Some of that support has been in contributions. Some has been through communication to the upper administration. We are grateful to you for this support. A heartfelt thanks to each and everyone of you.

Kenneth H. Niemeyer, D.V.M.
Assistant Dean for Student and Alumni Affairs



Dr. and Mrs. James Nave become Jefferson Club members

Pictured are Dr. and Mrs. James Nave and their 3-year-old daughter, Alisa.

Dr. and Mrs. Nave are now members of the University of Missouri Jefferson Club, Veterinary Medicine Chapter. Dr. Nave is a graduate of the College, Class of 1968. He becomes the first alumnus of the College to reach the Jefferson Club, Veterinary Medicine Chapter status.

Dr. Nave is a native of Protem, Missouri. Immediately after graduation he entered the Army and served in Viet Nam. After leaving the service, he went into practice in Las Vegas, Nevada. At the present time, he owns and manages several veterinary hospitals in Las Vegas.

He and his wife, Dedee, are active in community affairs. One of their present activities is to help establish an Art Center in Las Vegas.

Dr. Nave has been an avid supporter of the College and has employed numerous students in his practice when they have a free block. A number of our graduates also are employed by him.

Jefferson Club, Veterinary Medicine Chapter membership is achieved by a contribution of $10,000 or more to the College of Veterinary Medicine, University of Missouri.

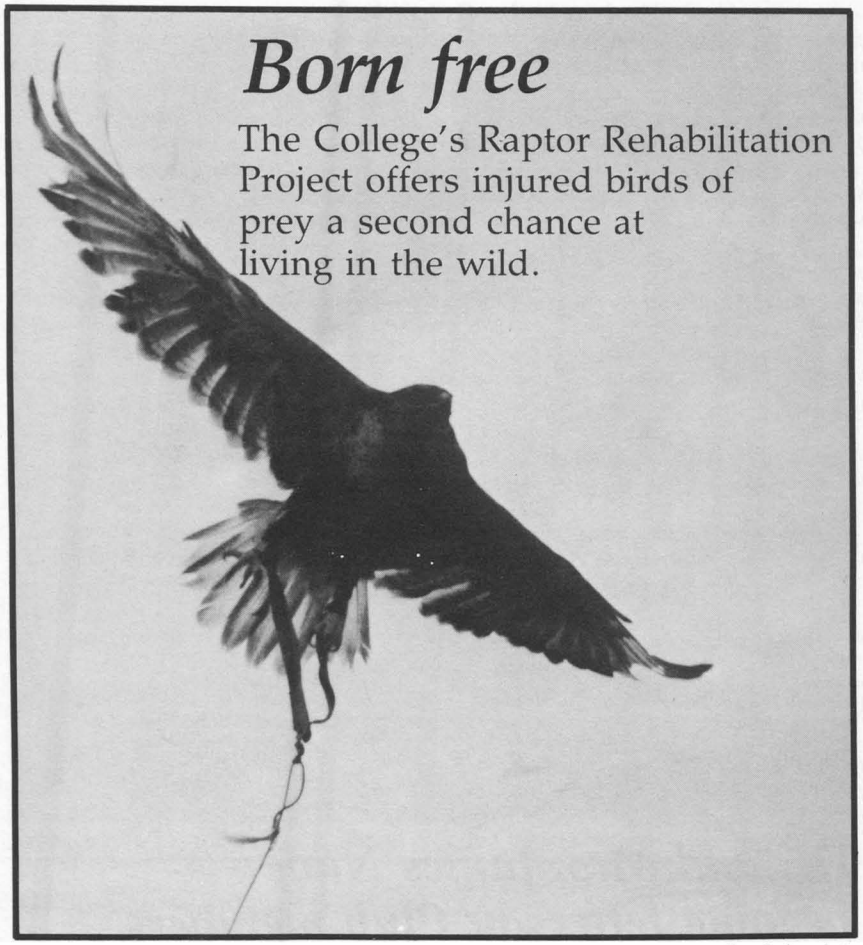

Born free

The College's Raptor Rehabilitation Project offers injured birds of prey a second chance at living in the wild.

Tom Parker photo

Greg Hassel, VMIII

The young red-tailed hawk coasted lazily just above the tree tops. Her crop was full of the tenderloins of a rabbit that had looked up a few seconds too late. The rabbit was her first kill in two days; in cool weather she didn't feed often. She glided down and landed lightly atop a utility pole, one of her favorite perches.

There she stood quietly and watched the pick-up truck crest the hill nearby. She didn't see the passenger window roll down, or the shotgun come down from the rack. She didn't hear the bolt slam home. She became anxious as the truck slowly rolled closer. She took to wing when the truck lurched to a stop at the foot of her perch, but it was too late. The gun sounded and she plummeted clumsily to the ground.

She lay in the tall grass with one twisted wing tossed obscenely across her back, dripping blood onto the brown earth. The misnomer "chicken hawk" drifted across the field as the truck sped away.

Ten years ago, that hawk would have died. No longer able to fly, she would have fallen prey to other predators. But today, if she's lucky enough to be found and brought to the College, Raptor Rehabilitation Project volunteers will try to repair the damage and send her back to her wild homeland. If she never flies again, she may live out her days in a zoo or research facility, helping to educate others on America's magnificent birds of prey.

The Raptor Rehabilitation Project was founded in 1972 by Dr. William Halliwell, Gary Weddle and Greg Ivins. An experienced falconer, Dr. Halliwell was on the faculty of the College's Department of Pathology. With two enthusiastic undergraduates in tow, Dr. Halliwell began obtaining the hardware, facilities, birds and professional assistance to get the project rolling.

During the first two years of the project, there was no official funding, although the Veterinary Teaching Hospital absorbed the cost of medical supplies. Volunteers constructed falconry hardware and tackle from what was available, or bought it with their own money. Residents and faculty members at the teaching hospital volunteered their services on a time-available basis.

In 1974, the teaching hospital no longer could afford to subsidize the entire project. The St. Louis chapter of the Audubon Society provided a three-year grant-in-aid to continue the project.

Dr. Halliwell left the College in 1976 and Dr. Donald Schmidt, a professor of veterinary pathology, took the reins. Dr. Schmidt was no newcomer to raptor rehabilitation; he personally had done much of the project's laboratory work. Dr. Schmidt ran the program for two years, until Dr. Stephen Stoll, a veterinary orthopedic surgeon, took over. Dr. Schmidt remains with the project in an advisory position. Dr. Stoll headed the project until his departure from the College last summer. Surgery resident John Robertson now directs the project.

Student involvement in the project has increased through the years. Where, in 1974 there were two students, there now are 20. Two local falconers recently joined up to educate students in handling the birds.

The extent of the volunteers' involvement depends on their interest. Most take on specific cases. A first case usually is a resident bird whose injuries preclude release; their familiarity with humans makes them easier for a novice to handle. Twice-a-month meetings allow discussion of all cases. As students progress through the College's curriculum, they become better able to handle more difficult cases.

Caring for project patients means more than meeting their medical needs. Fresh, high-quality rodents must be obtained from area research facilities to feed the birds. Volunteers repair and replace the tackle and hardware used, and even sew the gloves used for handling the birds.

The project's facilities have grown now to include an indoor ward to house up to 16 patients, an outdoor enclosure, and an enclosed flight area.

Necessity has spawned inventiveness in the project. Recently a red-tailed hawk caught in a coyote trap was presented. The injury required amputation of one leg. The student on the case developed a functional prosthesis for the bird. The bird is unreleasable, of course, but it provides a unique educational opportunity for student volunteers—a resident bird who can fly. Experience with this bird will help in conditioning releasable birds before

Continued on Page 11

Born free

From Page 10

they are returned to the wild.

In just the past two years, the Raptor Rehabilitation Project has seen 50 patients, ranging from bald eagles to redheaded woodpeckers, 12 of which were successfully returned to the wild. The project's purpose is three-fold: rehabilitation, education and research. The ultimate goal in each case is restoring the birds to their natural state. At the same time, a group of qualified individuals graduates from the program each year, available to competently care for injured raptors around the country, as well as assist other rehabilitation programs.

Research efforts stemming from the project include two studies currently under way at the College: one is an investigation of the duration of therapeutic blood levels of several antibiotics in raptors; the other involves gentamicin nephrotoxicity in red-tailed hawks.

Several publications also have come out of the project (see list below).

As the project enters its 11th year, two perennial problems remain: funding and patients. Money has always been a problem. The Audubon Society, which has graciously borne the brunt of expenses, is being asked again to renew its grant-in-aid.

Patients, of course, are the core of the project. Any wild bird brought to the teaching hospital will be cared for and returned to the wild, if possible, at no charge to whoever presents it. The existence of this program must be publicized to inform private individuals that there is a place to bring injured birds.

For more information about the Raptor Rehabilitation Project, contact Dr. John J. Robertson, University of Missouri Veterinary Teaching Hospital, 1600 E. Rollins, Columbia, MO 65211, or call (314) 882-7821.

Additional reading

1. Halliwell, W. H., Ivins, G. K., Schmidt, D. A., Weddle, G. "A Preliminary Report on the Hemotology and Chemical Profiles in Selected Birds of Prey," *Annual Proceedings of the American Association of Zoo Veterinarians* (1975).
2. Ivins, G. K. "Sex Determination in Raptorial Birds: A Study of Chromatin Bodies," *Journal of Zoo Animal Medicine* (1975), pp. 256-262.
3. Halliwell, W. H. "Raptors," *Zoo and Wild Animal Medicine*, edited by Murray Fowler, W. B. Saunders Co., 1975. pp. 219-290.

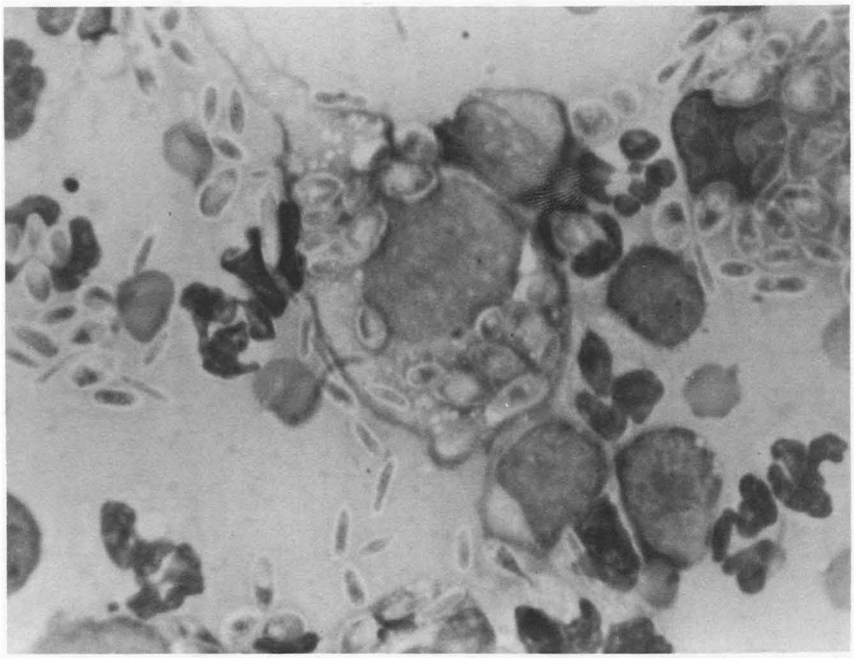

What's your diagnosis?

A cat with a draining lesion on the right forepaw was brought to a local veterinary clinic. Hairs around the opening of the tract were crusted with dried exudate. A smear was made of the exudate and a Wright's stain applied. In the illustration are the cells that were seen on the stained smear.

Answer on Page 12

Lorin Lawrence photo

Upjohn donates $500 to SCAVMA

SCAVMA President Jenifer Whiteside accepts a check for $500 from Dave Hornbacker, representative of The Upjohn Company. The Upjohn Company makes similar grants annually to all student AVMA Chapters throughout the United States as a part of the company's program to assist professional veterinary student groups. The grant may be used in any manner prescribed by the chapter membership.

Alumni Notes

Debbie Bruton (77), East Millstone, New Jersey. Is in a small animal practice and has a six-month-old son.

Robert Botts (57), Corvallis, Oregon. Is doing research for E.P.A. and enjoys the fish in Oregon.

Karen Campbell (79), Athens, Georgia. Currently is a second-year resident in the Department of Small Animals, University of Georgia. In addition, she is completing a master's degree.

Kenneth Kwochka (79), Gainesville, Florida. Was married 6-6-81. Is in a dermatology residency program at the University of Florida, College of Veterinary Medicine.

Thomas Overhulse (58), Upland, California. He is the program director for the Animal Health Technicians at Mount San Antonio Community College in Walnut, California.

John Woolsey (53), Las Cruces, New Mexico. John is retired from the USDA-APHIS.

Joseph Swink (72), Farmington, Missouri. Has bought and manages the Farmington Livestock Market Inc.

Arvel Mathewson (52), St. Joseph, Missouri. Has retired from his federal meat inspection post after 30 years of service.

Paul Caciolo (80) New York City, New York. He is with the Animal Medical Center as a dermatology resident.

Daniel Carey (78), St. Peters, Missouri. Dan is associated with Ralston-Purina. He is a veterinary consultant for swine.

Gerald Carey (68), Blue Springs, Missouri. He is active in a small animal practice.

John Fields (68), Carbondale, Illinois. Is in a solo small animal practice.

Herb Griffith (68), Whittier, California. Has an AAHA practice with numerous avian cases. In addition, Herb is serving his first term on the school board.

Stuart Levin (68), Okemos, Michigan. Is a board-certified veterinary pathologist and assistant professor of pathology at Michigan State University's veterinary college.

Ron Macedo (76), Dallas, Oregon. Doing great! He invites everyone, all 1,372 alumni, to visit him.

C. A. Martin (77), Warrensburg, Missouri. Just got married!

Catherine Ruddy (80), Williamsville, Missouri. Just got married. In addition she is working in a mixed practice.

Warren Schilb (50), Oklahoma City, Oklahoma. Practicing in same location since 1956. In addition, he has a 2-week-per-year practice with a 26-man partnership in Grand Cayman, BWI.

David Simmons (79), Danville, California. Dave is in a multi-man small animal practice in Danville.

Donna Kay Walton (79), Ithaca, New York. She is about to complete a comparative dermatology residency at Cornell University.

Marlyn Whitney (79), Lafayette, Indiana. She is currently in a residency/graduate program in veterinary clinical pathology at Purdue.

Al Dietzel (73), Decatur, Indiana. He has been promoted to veterinary technical service manager for Central Soya.

Jerry Eber (77), Shelbyville, Missouri. He is employed by the USDA as a brucellosis epidemiologist in Jefferson City, Missouri.

Jack Phillips (77), St. Peters, Missouri. Reports nothing to report.

Steven Smith (78), Kansas City, Missouri. Owns and operates a solo small animal hospital in Kansas City.

Stephen Becker (78), Teterboro, New Jersey. He is the director of veterinary pathology for Metpath/Corning.

David Miles (52), Blytheville, Arkansas. Is managing a small animal hospital in Blytheville.

Daniel Weddle (81), Mount Ayr, Iowa. He is now associated with the Hilltop Veterinary Clinic in a general practice.

George Fischer (54), Amity, Missouri. George has retired from the U.S. Army and is presently living on a farm near Amity.

In memoriam

Dr. Stephanie Dale, Class of 1980, died February 8 in St. Louis. She had been employed in a small animal practice in St. Louis.

Friends may make memorial contributions in her name to the Veterinary Medical Memorial Scholarship Fund. Checks, payable to the University of Missouri, should be sent to Dr. Kenneth Niemeyer, College of Veterinary Medicine, W-203 Veterinary Medicine Building, University of Missouri, Columbia, MO 65211.

Diagnosis *From Page 11*

Sporotrichosis. Cigar-shaped bodies characteristic of *Sporotrichum schenckii* were found in the exudate and were isolated in the laboratory by cultural methods.

Sporotrichum schenckii is a fungal agent commonly found in the soil. It gains entrance to the skin of man or animal by means of a penetrating agent such as a thorn or a splinter.

D. A. Schmidt, D.V.M.
S. L. Stockham, D. V. M.
UMC Department of Veterinary Pathology
Horton Veterinary Clinic
Columbia, Missouri

Missouri Veterinarian
Vol. 32, No. 1 (1982)

Editor .....*Greg Hassel*
Managing Editor.....*Kathy Casteel*
Faculty .....*Drs. E. Brown & R. Miller*

Veterinary Medical Review
College of Veterinary Medicine
and Cooperative Extension Service

Editor: Kathy Casteel
W-203 Veterinary Medicine Building
College of Veterinary Medicine
University of Missouri-Columbia
Columbia, MO 65211

Marriott Inn

Return Requested 22.0 · 11:30

• **Supported in part by the UMC Extension Division** • **University of Missouri is an equal opportunity institution.**