MAY, 1936 RESEARCH BULLETIN 240

UNIVERSITY OF MISSOURI COLLEGE OF AGRICULTURE
AGRICULTURAL EXPERIMENT STATION

F. B. MUMFORD, *Director*

The Development of the Mammary Glands of the Goat

C. W. TURNER AND E. T. GOMEZ

(Publication Authorized May 16, 1936)

COLUMBIA, MISSOURI

ABSTRACT

A study is reported of the embryonic and fetal differentiation of the mammary gland (udder) of the goat. The mammary streak was observed in a 25 day (0.5 cm.) embryo, the fully formed mammary bud in 6.0 cm. male embryos, early stages of the teat proliferation and the growth of the primary sprout at the 11.4 cm. stage and the formation of the cistern of the teat and gland (from the primary sprout) and considerable development of the secondary sprouts to form the primary ducts in the 88th day (22.9 cm.) stage. From that period until birth further growth and canalization of the ducts occurs.

Slow growth of the duct system takes place during the prepubertal period which is accelerated during the successive estrus cycles.

During the first half of pregnancy, the greater part of the proliferation of the lobule-alveolar system takes place, whereas during the latter part the characteristic change was a gradual increase in the size of the lumina of the alveoli resulting from an accumulation of secretion.

The Development of the Mammary Glands of the Goat

C. W. Turner and E. T. Gomez

I. EMBRYONIC AND FETAL DEVELOPMENT

As a foundation for the study of the physiology of milk secretion it is imperative that rather complete information be available concerning the anatomy of the mammary glands of the form to be studied. Consequently, the anatomy of the glands of the common, small experimental animals including the mouse, rat, rabbit, guinea pig, cat and dog have been examined in more or less detail in our laboratory in order to detect species differences in development and structure and their response to the changes in the reproductive organs during recurring estrum, pregnancy, lactation and involution.

Experiments having as their objectives the duplication of the various stages of growth and secretory activity previously noted have contributed much to present knowledge of the relation of the hormones of the ovary and pituitary to the growth and function of the mammary gland. It is natural that attention be turned to the common domestic animals such as the cow and goat with the objective of determining whether the information now available can be used to practical advantage in dairy husbandry. Because of the relatively small size and therefore smaller original cost and maintenance, the improved dairy goat is ideal for the purpose. Not only is the goat second to the dairy cow as a commercial source of milk, but the relatively large udder and ease of milking contribute to the suitability of the goat for further experimental work in milk secretion where the determination of the yield and composition of the milk is important. In addition the information so gained may be of direct practical application.

The object of the present bulletin is to present the results of a study of the normal growth of the udder of the dairy goat from the earliest stages of embryonic and fetal life to the time of functional maturity.

Material and Technique

The embryos and fetuses used in this study were for the most part specimens of known age. A few specimens of unknown age were obtained from pregnant goats which had died in the course of other experiments (Table 1). The primiparous does were examined by laparotomy under general anesthesia at timed intervals after being bred. If the does were pregnant, they were then sacrificed. The udders of the does were taken for the study of the growth of the gland during the first pregnancy.

The embryos and fetuses were quickly weighed and measured and then fixed in Bouin's fluid. The embryos were embedded in toto and

TABLE 1.—WEIGHT AND MEASUREMENT OF GOAT EMBRYOS AND FETUSES AT VARIOUS INTERVALS AFTER CONCEPTION[1]

Days After Conception	Sex of Fetus	Number of Fetus 1 Weight grams	Number of Fetus 2 Weight grams	Number of Fetus 3 Weight grams	Measurements of Fetus Crown-Rump Length cm.	Measurements of Fetus Height cm.	Elliott, Hall and Huggett (1934) Days After Conception	Number of Fetus 1 Weight grams	Number of Fetus 2 Weight grams	Number of Fetus 3 Weight grams
15	—	.069	--------	------	------	------	---	------	------	------
25	—	--------	.210	------	.48	------	---	------	------	------
	—	--------	.208	------	.50	------	---	------	------	------
37	F	2.243	--------	------	2.90	1.5	---	------	------	------
45*	M	7.200	--------	------	6.09	2.1	---	------	------	------
45–47*	M	10.200	--------	------	6.35	3.55	------	------	------	------
55*	M	56.5	--------	------	11.43	5.82	---	------	------	------
55*	M	--------	50.0	------	11.43	5.82	---	------	------	------
----	--	--------	54.0	------	11.43	5.82	---	------	------	------
							68	100.0	------	------
88*	F	367.0	--------	------	22.86	6.98	85	------	254.0	------
								------	278.0	------
108	F	449.0	--------	------	23.50	17.78	105	------	730.0	------
									690.0	------
135	F	--------	648.0	------	26.5	16.57	136	------	------	833.0
	F	--------	578.0	------	25.4	16.57		------	------	960.0
										952.0
140*	M	949.0	--------	------	27.94	17.78	139	1974.0	------	------
145	F	--------	1724.0	------	30.48	21.34	146	------	2280.0	------
	F	--------	1440.0	------	30.99	19.32	---	------	2910.0	------
150	F	--------	--------	1352.0	35.56	22.86	148	3820.0	------	------
	M	--------	--------	2687.0	38.10	25.40	(1st day)			
	M	--------	--------	1584.0	36.83	24.03				
At birth	M	2680.0	--------	------	------	------	151 (1st day)	1850.0	------	------
At birth	F	2830.0	--------	------	------	------				

*Calculated age of the fetus.
1. The average period of gestation in the goat is 150 days.

sectioned serially from 8 to 10 microns in thickness. In the specimens from 37 days after conception until birth only the region of the groin containing the mammary apparatus was fixed and sectioned. In all instances, the sectioned material was stained in Delafield's hematoxylin and eosin. The sex of the fetuses was determined by an examination of the external genitalia.

During the study of the extrauterine development, the mammary apparatus was studied grossly and by the aid of histological sections. As far as possible, whole mounts of the glands were also prepared according to the method previously described (Turner and Gomez, 1933).

The goats used in the study of the fetal and pregnant development were of the Toggenberg breed. While they were all unregistered animals, they were chiefly high grades and of pure breeding. They were from stock possessing large udders and good milk production.

Embryonic Development

The embryonic development of the mammary glands of a number of experimental and domestic mammals has been studied. This literature has been reviewed in detail in previous studies reported from our laboratory and needs only brief mention here (Turner, 1930-31, Turner and Gomez, 1933-34). Rein (1881) appears to be the only investigator to study the development of the udder of the goat and his observation is confined to a single 2.8 cm. embryo.

The Mammary Streak and Line.—Previous studies have shown that the earliest stage of development which later differentiates into the mammary apparatus consists in the enlargement of the cells of the stratum germinativum on either side extending from the anterior to the posterior limb buds. This stage is called the mammary streak. The cells of the mammary streak proliferate and become slightly elevated above the surface to form faint parallel lines called the mammary lines.

The earliest embryo obtained 15 days after conception was in the somite stage and showed no indication of the mammary streak. Twin embryos obtained 25 days after conception (0.48 and 0.50 cm long) showed in cleared preparations on either side in the region of the ventrolateral limiting furrow, a light streak extending from the anterior to the posterior limb buds (Fig. 1). Cross sections in this region revealed that the streaks were composed of single layers of elongated cells (the Malpighian layer) distinctly larger than those adjoining. These cells are covered by a layer of flattened epitrichial cells (Fig. 2). This stage is believed to represent an early mammary streak.

The mammary line stage was not observed but it would appear that this stage should be reached in embryos about 30 days after conception.

The Mammary Bud.—At intervals along the mammary lines, further proliferation of the germinal layer occurs which causes slight spherical elevations to appear. This stage of development of the mammary bud has been designated as the *mammary crest* (or lens-shaped stage) and with further proliferation the mammary hillock (or half-moon shaped stage). With further growth, there is an invagination of the structure into the underlying mesenchyme tissue and a rounding up to form the completely rounded mammary bud (Table 2).

Rein (1881) presented a figure of the developing mammary bud of a 2.8 cm. goat embryo which was in the crest or lens-shaped stage (Fig. 3). In our 37-day stage (2.9 cm. crown-rump length) the development was slightly more advanced, between the hillock and bud stage (Fig. 4). It is probable that the fully developed bud stage is reached at about the 3.0 cm. stage. This is somewhat later than for the corresponding stage in cattle and sheep. The mammary bud stage was observed in twin

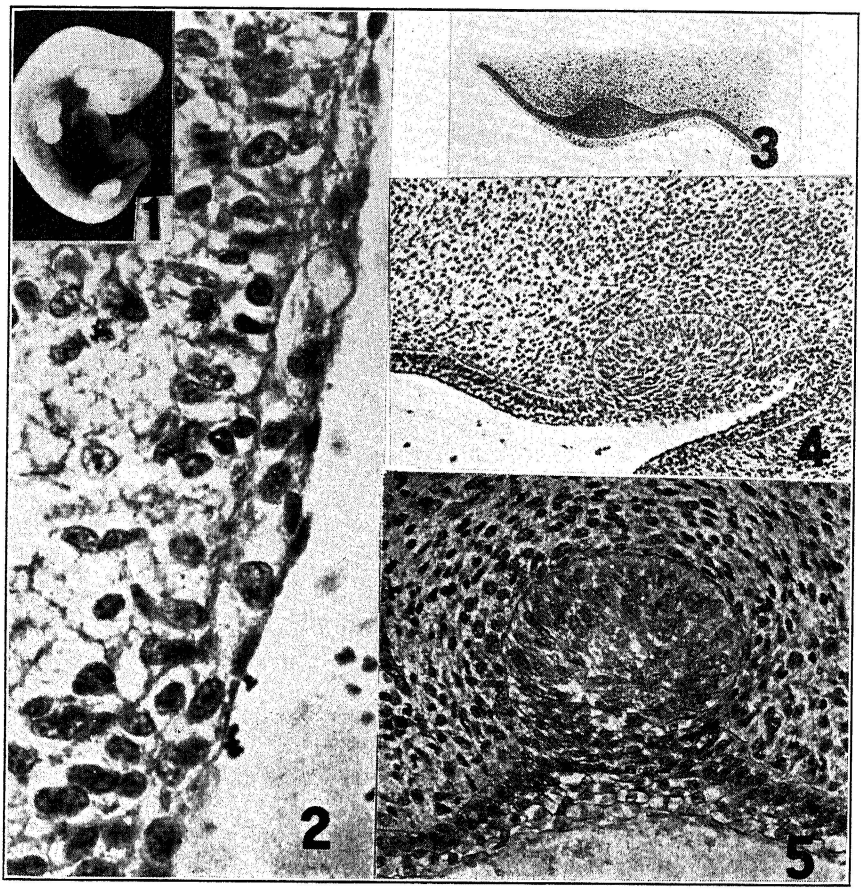

PLATE I

Fig. 1.—Side view of a 25-day (0.210 cm.) old goat embryo, showing the faint mammary streak extending from the axilla of the anterior limb to the posterior limb buds. (x2).

Fig. 2.—Microphotograph of a section through the mammary streak of a 25-day old goat embryo (Fig. 1). Note the large irregular shaped cells of the Malpighian layer comprising the mammary streak and the outer layer of flattened epitrichial cells. (x60)

Fig. 3.—Section through the developing mammary bud (lens-shaped stage) of a 2.8 cm. goat embryo (From Rein) slightly enlarged.

Fig. 4.—Microphotograph of a section through the developing mammary bud of a 2.9 cm. mammary hillock (37-day old) goat fetus. (x30).

Fig. 5.—Microphotograph of a section through the mammary bud of 6.0 cm. (about 45-day old) male goat fetus. (x30).

male embryos 6.0 and 6.9 cm. (Fig. 5). At this time the buds were well invaginated in the mesenchyme tissue and were almost spherical in shape. The usual histological elements were present in the buds, namely, the Malpighian layer resting upon a distinct basement membrane, and a group of central cells.

TABLE 2.—COMPARATIVE DEVELOPMENT OF THE MAMMARY GLAND

Species	Stage of Development						Authority
	Mammary Streak		Mammary Line		Mammary Bud		
	Age Days	Length Cm.	Age Days	Length Cm.	Age Days	Length Cm.	
Mouse	10	---	12	---	13	---	Turner & Gomez (1933)
Rat	11	---	13	---	14	---	Henneberg (1900)
	--	---	--	---	15	---	Myers (1917)
Guinea Pig	--	---	21	---	--	---	Schickele (1899)
	--	---	20	---	25	---	Turner & Gomez (1933)
Rabbit	--	---	--	1.5	--	1.8	Rein (1882)
Cat	--	---	--	1.0	--	---	Schultze (1892)
	--	---	--	---	--	4.8	Gisler (1922)
Swine	--	---	--	1.5	--	---	Schultze (1892)
	--	---	--	1.0	--	---	Profé (1899)
	--	---	--	1.64	--		Keibel (1897)
	--	---	--	---	--	5.0	Rein (1882)
Goat	25	.4 –.5	--	---	--	6.0	This paper
Sheep	--	---	--	.9 – 1.0	--	2.5	Profé (1899)
Cattle	--	1.4	--	1.7	--	2.5	Turner (1930)
Horse	--	1.5	--	2.2	--	8.0 (?)	Profé (1899)
Man	--	.4 – .68	--	1.4	--	---	Hirschland (1899)
	--	---	--	.9	--	2.3	Brouha (1905)
	--	---	--	.8	--	1.7	Lustig (1916)

The Primary Sprout.—The development of the primary sprout is of special interest because it is at this stage in the progressive development of the mammary gland that the greatest species differences appear (Table 3). In the goat only a single sprout was observed.

Examination of the male embryos 11.4 cm. long showed that the primary sprout had begun to grow upward into the teat. It was composed of a solid mass of cells with a slightly bulbous growing end (Fig. 6). The mammary bud at this stage is beginning to disappear. This stage of development is so similar to that observed in cattle that no details are required.

TABLE 3.—COMPARATIVE DEVELOPMENT OF THE MAMMARY GLAND

Species	Primary Sprout		No. of primary sprouts	Authority
	Age Days	Length Cm.		
Mouse	17-18	----	1	Turner & Gomez (1933)
Rat	18	----	1	Myers (1917)
Guines Pig	25-30	----	1	Turner & Gomez (1933)
Rabbit		7-8	4-8	Rein (1881)
Cat	----	10.9	2–4–6	Gisler (1922)
Dog*	----		6–12	Christ (1905)
	----	----	2–20	Kaeppeli (1918)
Swine	----	7.5	2	Rein (1881-82)
Sheep	----	8.0	1	Rein (1881-82)
Goat	45-50	11.4	1	This paper
Cattle	----	12.3	1	Turner (1930)
Horse	----	9.5	2	Hamburger (1900)
Man	----	----	8–25	Klaatsch (1884)

*Figures represent the number of primary ducts, counted on adult animals.

Teat Development.—The growth of the teat follows the proliferation type of development similar to that observed in the guinea pig, rabbit, swine, sheep, dog, cat, cattle and others and differs from

that observed in the mouse and rat. In the latter, the teat develops as the result of an epithelial ingrowth surrounding the mammary bud. In the goat the mesenchyme tissue surrounding the bud begins to proliferate causing the bud to be elevated above the surrounding surface (see figure of 11.4 cm stage). At the same time the primary sprout begins to grow into the newly forming teat. The growth of the teat causes the mammary bud to lose its spherical shape and to flatten out into a cone-shaped structure at the apex of the teat.

In an 88-day (22.86 cm. long) female goat fetus, the primary sprout had canalized, forming the cistern of the teat. The skin of the teat had begun to differentiate and hair follicles were prominent up to the end of the teat. In this respect, the teat of the goat differs from that of cattle as the latter are free of hair.

Development of the Duct System.—The growth of the primary sprout and its gradual evolution into the gland parenchyma is of especial interest due to the fact that it contains all the potentialities for development into a functional mammary gland. It is unnecessary to give all the details due to the great similarity of the developing goat duct system to that of cattle. In an 88-day (22.86 cm. long) fetus, the primary sprout had canalized to form the cistern of the teat and was beginning to enlarge to form the cistern of the gland. Secondary sprouts had developed earlier as they had already canalized to form the primary ducts whose function later is to convey the milk into the gland cistern (Fig. 7).

Whole mount preparations in late fetal stages showed an extensive growth of the duct system. These ducts were characterized by extensive branches from the walls of the ducts in all planes. These bud or sprout-like outgrowths are believed to be true ducts and not the precocious development of an alveolar system (Fig. 8).

Form of the Udder.—In the larger mammals, the mammary glands develop into structures called the udder. In the selection and judging of dairy animals considerable attention is given to the form and size of this structure in gauging the potential milk production of the individual. It is of considerable interest, therefore, to note the development of the form of the udder and its relation to the development of the gland tissue. It was shown in the case of cattle (Turner, 1931) that the form of the udder develops very early in fetal life. Long before the duct system develops above the teats, the mesenchyme tissue has increased to form udders of definitely variable form. It seems reasonable to believe that the form of the udder is independent of the development of the gland within.

While a complete series of udders are not available, the udder of the goat appears to be similar to the cow in showing a characteristic form

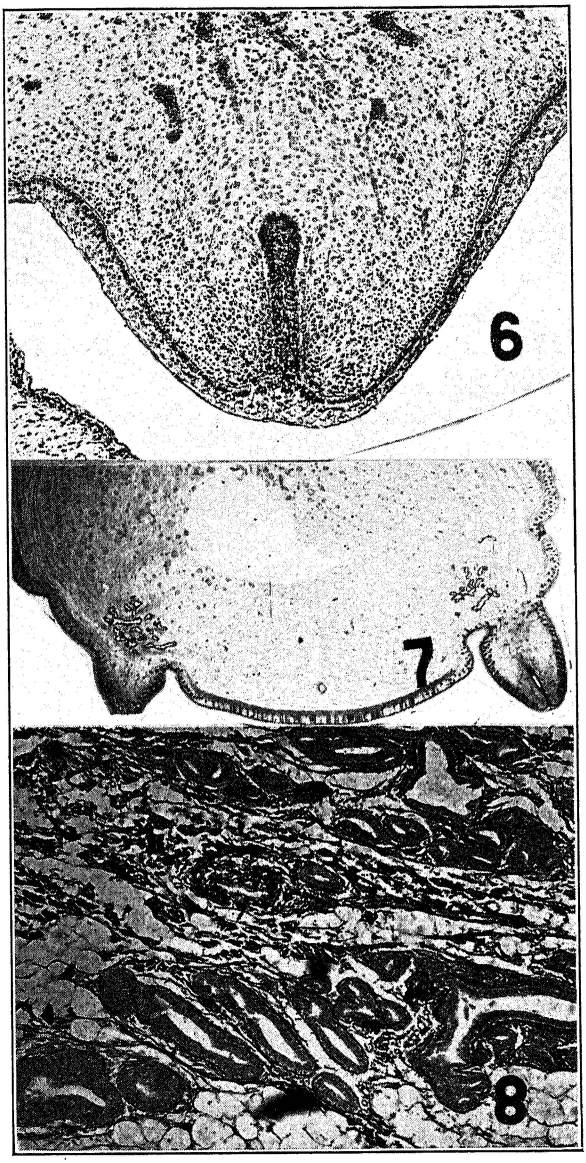

PLATE II

Fig. 6.—Microphotograph of a section through the teat of an 11.43 cm. male goat fetus showing a stage of development of the primary sprout. (x30).

Fig. 7.—Photograph of a section through the udder of an 88-day old female fetus (22.86 cm. long) showing the extent of development of the glandular parenchyma (duct system) and the fully formed udder (x5)

Fig. 8.—Microphotograph of a section of the udder of an 88-day old female fetus showing the cellular structure of the duct system (x60).

at a very early stage of fetal development. A well formed udder was present in the 22.8 cm. stage. In this udder made up chiefly of embryonic mesenchyme cells, there appears to be a beginning of differentiation into fibrous connective tissue which later forms the support for the gland tissue. The deposition of fat has also begun at this time and continues until the udder is composed of a pad of fat. A fetus 145 days old showed that this process was complete.

The formation of connective tissue cell whorls observed in cattle were also observed in the 22.8 cm. stage of the goat.

In the males, udder development is entirely lacking. The teats are located on either antero-lateral aspect of the scrotal sac or a short distance in front of the sac. As a consequence, the fatty pad of which the female udder is composed is absent and the space into which the duct system may develop is circumscribed.

II. PREPUBERTAL DEVELOPMENT

The udder of the goat at birth consists of a structure composed of a fatty pad of connective tissue which gives it essentially mature form. The gland consists of the cistern and duct system which extends for only a short distance into the fatty pad. The various structures of the mature teat are largely differentiated. As at this stage of development, the duct is of chief interest, further details of the growth of this system will be presented.

Growth of the Duct System in the Female.—The extent of the growth of the duct system of the mammary gland from birth to the approach of the first estrum varied considerably in the species already examined. In some species little or no growth of the duct system occurs while in others the ducts continue to develop slowly. In the female goat during this period, the duct system continues to grow.

At birth*, the duct system is quite extensive with numerous side branches sprouting from all parts of the principal ducts. The number and type of the branches, as observed in the whole mounts, might cause one to think that the gland at this time was composed of all the structures in a completely developed gland, the lobule-alveolar system. Examination of sections of the glands reveal that these elements consist chiefly of ducts lined with a two-layered epithelium. The short wide branches of the smaller ducts which give the impression of a group of solid alveoli are also composed of similar cellular elements except that the distal ends (end buds) are made up of solid masses of epithelial cells (Figs. 9 and 10).

Glands obtained at intervals during this period show considerable variation but in general the older animals have the more extended duct

*Due to the fact that kids frequently begin to secrete milk precociously, it has been assumed by some that the structure of the mammary glands of goats develop precociously. For this reason the type and extent of growth has been studied in detail in a number of animals.

system. The branches of the ducts which earlier might have been confused are true ducts. The compact duct system develops in several layers (or planes) in the fatty pad composing the udder and for the ducts to be seen satisfactorily it is necessary to dissect away the overlapping branches. It should be clearly understood that the figures of the whole mounts thus represent only isolated main ducts or branches of the duct system rather than the entire gland.

Histologically, the mammary gland throughout the prepubertal period remains the same except for the increase in extent and degree of arborization of the ducts. The multiplicity of small branches may appear as alveoli unless carefully examined in sections and whole mounts.

As a result of these observations there is a firm conviction that the prepubertal stage of gland development in the goat is quite similar to that observed in certain other species, namely, the presence of a greatly branched duct system, which because of its condensed nature may have been thought to be a precocious lobule-alveolar system (Figs. 11, 12, and 13). The precocious lactation which is frequently observed in kids and in nulliparous sexually mature females is believed to be due to the capacity of the epithelial cells lining the cistern and duct system to secrete milk when under suitable hormone stimulation as has been demonstrated in the rabbit by Gardner, Gomez and Turner (1935).

Growth of the Duct System in the Male.—While the intrauterine development of the male and female glands has many points of similarity, the extrauterine development is quite different. The series of male mammary glands obtained indicate that the rate of duct growth is extremely slow. A comparison of whole mounts of glands indicate that the diameter of the duct system at six months (1 cm. in diameter) is about twice the diameter observed at birth. A gland from a four year old male showed a diameter only five times greater. The duct system extends beyond the base of the teats and the growth appears to parallel the increase in size of the teats.

In the whole mount preparations, the ducts appeared to be somewhat enlarged with secretion, masking to some extent the individuality of the smaller branches of the duct system. Examination of the ducts revealed the two-layered epithelium characteristic of these structures (Figs. 14-18).

While in the normal male goat, the mammary gland remains rudimentary throughout life, there are a few reports in the literature since the time of Aristotle indicating that the mammary glands of bucks may enlarge and become functionally active. These reports will be discussed in more detail in another publication. Bourdelle and Bressou (1929) studied the anatomy of the mammary gland of a male lactating goat. From the figures presented; it would appear that the gland is composed of a rather extensive duct system, which is filled with secretion.

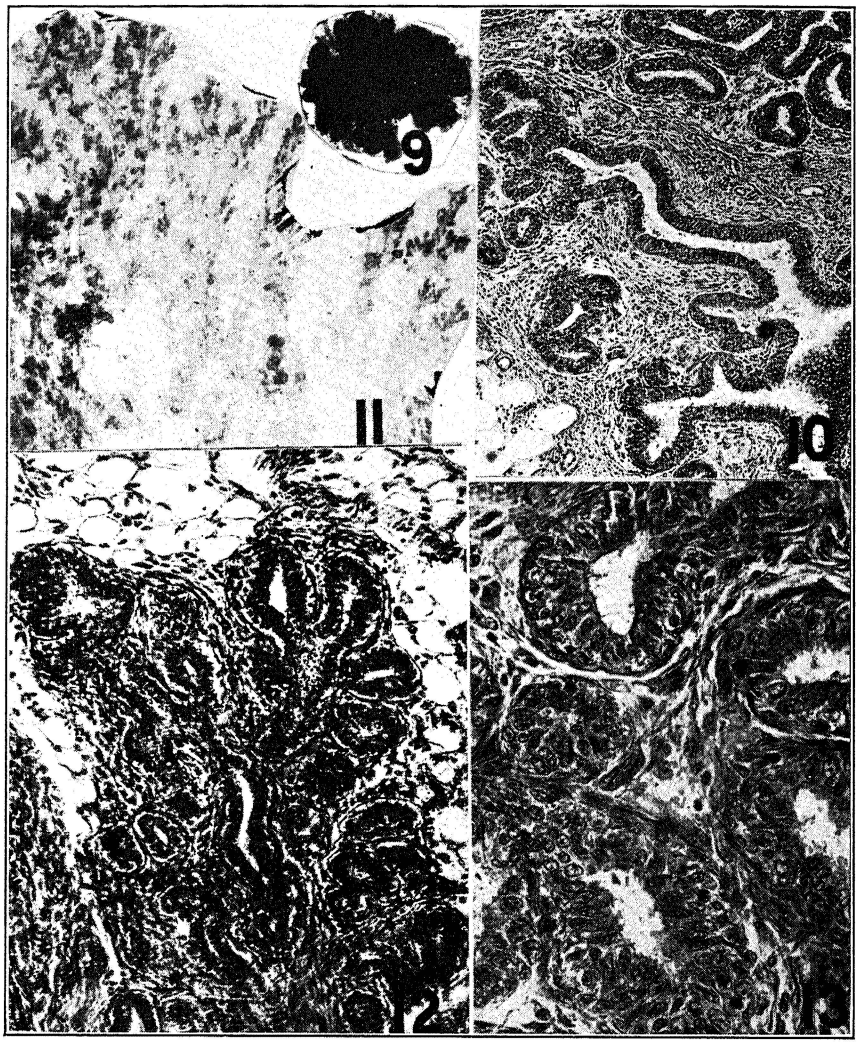

PLATE III

Fig. 9.—Photograph of a whole mount of the mammary gland of a female goat at the time of birth. The short lateral buds arising from all planes of the main ducts made it difficult to demonstrate the true condition of the glandular elements. (x1¾).

Fig. 10.—Microphotograph of a section of a female goat mammary gland at the time of birth. Note the two-layered epithelial lining of the wall of the duct system (x52).

Fig. 11.—Whole mount of a dissected portion of the mammary gland of a female goat after it has been stimulated by several estrus cycles. Note the enlarged ducts with numerous lateral outgrowths. (x1¾).

Fig. 12.—Microphotograph of a section of the mammary gland shown in Fig. 11. Note the lumen of the lateral buds are continuous with the lumen of the large duct. (x26).

Fig. 13.—Microphotograph of a portion of the gland shown in Fig. 12. Note the two layered epithelium lining the walls of the ducts. (x52).

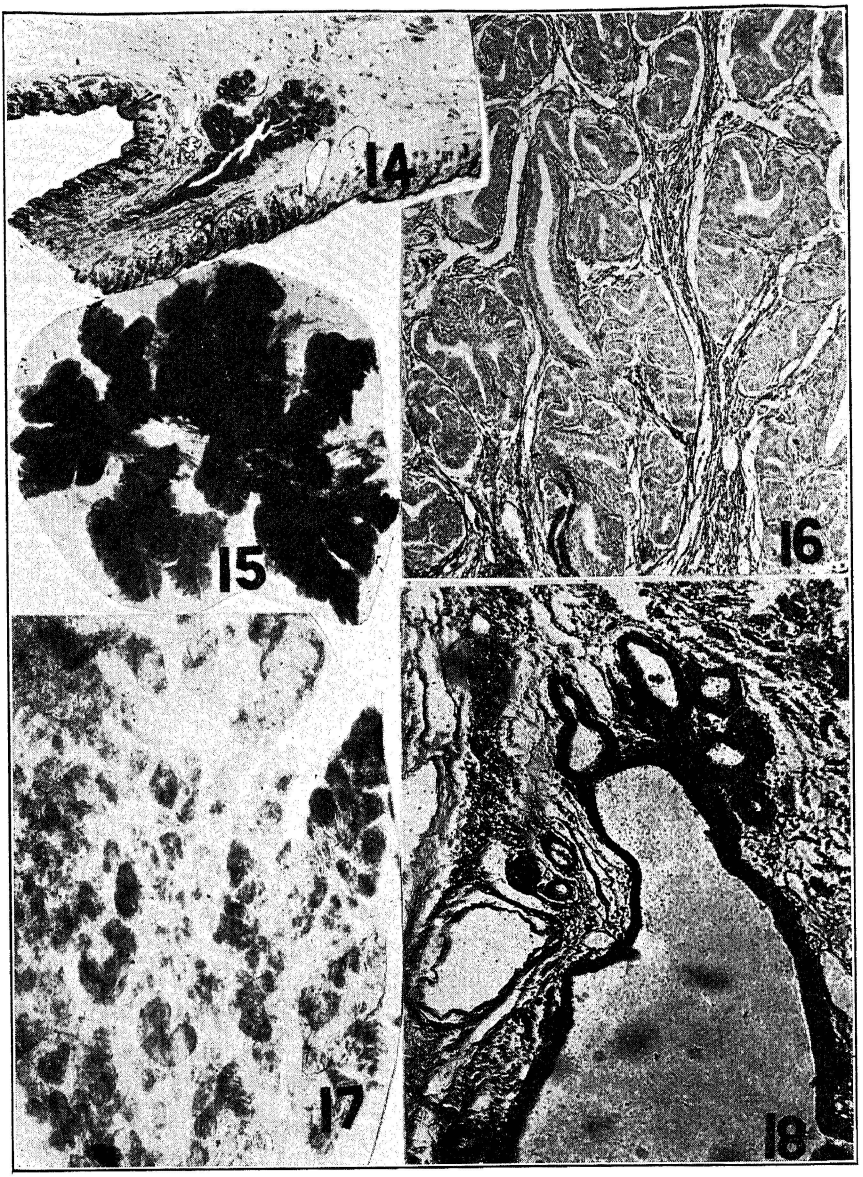

PLATE IV

Fig. 14.—A longitudinal section through the teat and gland of a male goat one week after birth showing the extent of the mammary gland. (x5½).

Fig. 15.—Photograph of a whole mount of the mammary gland of a male goat one week after birth. Taken from the same animal as that shown in Fig. 14. (x 4).

Fig. 16.—Microphotograph of a section of the mammary gland shown in Fig. 14. (x52).

Fig. 17.—Portion of a whole mount of the mammary gland of a male goat four years of age. The ducts and lateral outgrowth are distended due to the presence of secretion in the lumina (x3½).

Fig. 18.—Microphotograph of a section through the distal end of a duct. Note the large lumen of the ducts and lateral outgrowths. Alveolar structures are absent. (x52).

III. PUBERTAL DEVELOPMENT

The female kid will normally reach sexual maturity during the fall after its birth. This is usually at about six months of age although some does have been known to kid when less than nine months old (Shaw 1918-1934). With the approach of puberty and the gradual development of follicles in the ovaries, the mammary duct system begins to grow rapidly, resulting in a very dense arborization of the duct system. Further bud-like outgrowths form in all planes of the larger ducts (Figs. 11-13). At the free end of these branches multiple sprouts representing the anlagen of the lobule ducts begin to form.

The duration of the estrus cycle has not been extensively studied. Shaw (1918) reported that does most frequently come in heat at intervals of 17 to 21 days. Kupfer (1928) reported that ovulation recurred at regular three week intervals in Swiss goats. Observations on the Boer goat in South Africa indicated that a new estrum may be expected 19, 20, or 21 days after the beginning of the preceding estrum. As the goat is a seasonal breeder (Turner, 1936) there is an anestrus period extending from March until August.

The changes in the mammary gland during the early estrus cycles were not observed. However, the glands obtained from animals which had gone through several estrus cycles, in whole mounts, showed an extensive growth of the duct system and numerous bud-like outgrowths in various planes of the lateral walls and the free ends of the ducts. The condensed nature of the multiple outgrowths appeared somewhat like an unexpanded lobule-alveolar system. Microscopic examination of sections of the glands revealed that these outgrowths were lined with a double-layered epithelium until close to the end-buds where the cells gradually lose a definite arrangement. As it is generally agreed that ducts are lined by a two-layered epithelium, while alveoli are lined by a single layer of cells, these structures are believed to be ducts.

In general, the essential features of the gland parenchyma after the passage of a number of estrus cycles, are essentially the same as at the onset of puberty except for an extension in the arborization of the duct system. While the ducts so formed may be considered as a stage of lobule development, the formation of true alveoli (differentiated from duct end-buds by the number of layers of epithelial cells and difference in the number of such structures) was not observed in nulliparous females. That the growth of alveoli does not normally occur during a succession of estrus cycles is further indicated by the fact that during the involution process after lactation, the alveoli gradually degenerate and by approximately 75 days after the last milking only a duct system remains (Turner and Reineke, 1936).

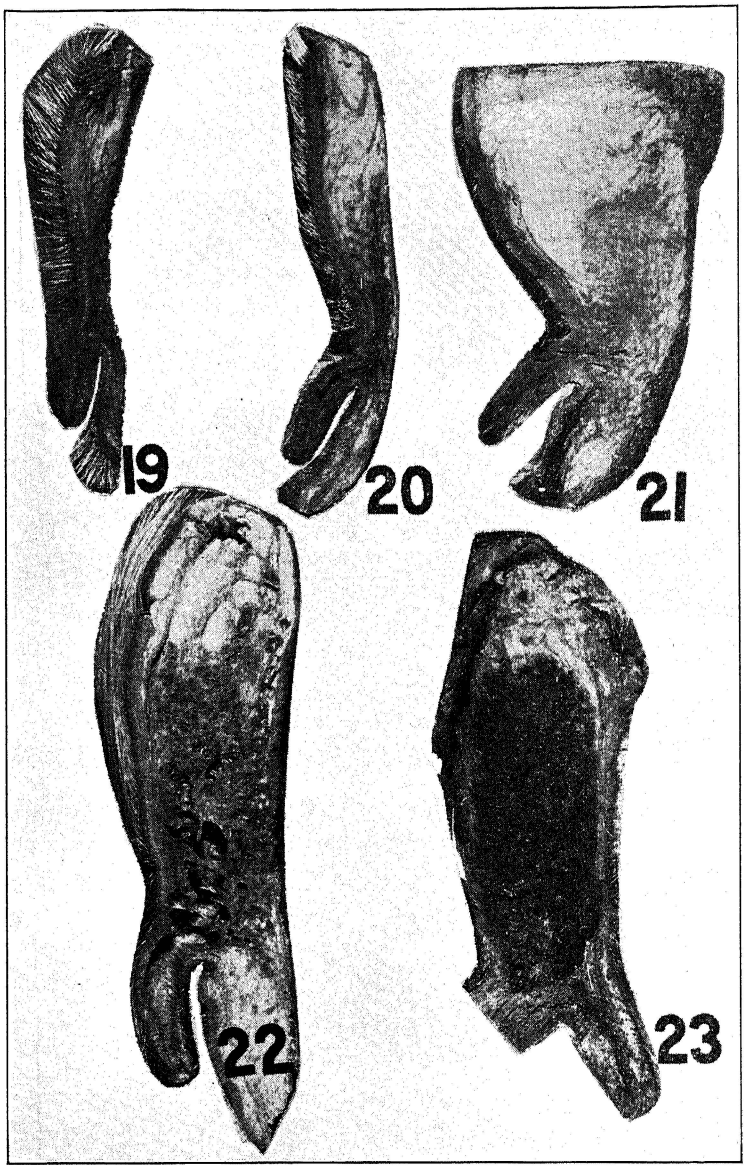

PLATE V

Fig. 19.—A longitudinal section through the teat and gland of a female goat at the time of conception. Note that the udder consists only of a fatty pad, the glandular elements being confined to an area at the base of the teat. (x1).

Fig. 20.—Goat udder 15 days after conception. Note the glandular parenchyma invading the fatty pad. (x1).

Fig. 21.—Goat udder 25 days after conception. A further increase in growth of the glandular elements had taken place. (x1).

Fig. 22.—Goat udder 37 days after conception. Note that the fatty tissue has practically all been replaced by glandular elements. The cistern of the teat and gland is dilated. (x1).

Fig. 23.—Goat udder 88 days after conception. The growth of the gland is about complete at this time. Note the compact mass of glandular elements. (x1).

IV. PREGNANCY

During pregnancy the stages of growth and development are of unique interest because it is only at the close of this period that the process culminates in normal milk secretion. During the first pregnancy covering a period of about 150 days (Asdell, 1919) the pubertal udder of the goat consisting of a gland cistern with a branching duct system is transformed greatly in size and complexity of structure.

The series of glands available for this study were obtained from young primaparous does. The first stage of pregnancy obtained (15 days) showed that the gland still consisted of a branching duct system. The branches and end-buds stained deeply indicating that rapid growth of the duct system was occurring (Fig. 19 and 20).

After 25 days of pregnancy the duct system had become further extended and arborized, but the branches were rather compact. Whole mounts of the gland would lead one to believe that already definite lobules were forming. However, histological examination of sections through the longitudinal course of the ducts showed the lumina of the lateral branches to be continuous with the developing lumina of the bud-like sprouts and are believed to represent the anlagen of the finer lobule ducts and alveoli. They were observed to be lined with a double layered epithelium (Figs. 21, 26, and 27).

Whole mounts of branches of the duct system of glands of the 37 day stage were visible only along the periphery. In the region close to the cistern and larger ducts, the proliferation of lobules with the multitude of alveoli was in progress. The older ducts and their branches have thus reached the stage of alveolar proliferation, whereas the younger ducts, especially around the periphery, were still growing in length and complexity.

At this stage, a cross section of the entire udder half showed a teat and gland cistern of considerable size with large ducts extending for considerable distances into the gland parenchyma. The fatty pad of the udder still appeared free of gland tissue in front and at the upper rear section (Figs. 22, 28 and 29.)

By the 88th day of pregnancy (about half term) the sectioned udder revealed a compact mass of gland tissue filling almost the entire udder; that is, little of the fatty pad was still visible. Because of the extensive development whole mounts of the gland were very inadequate for microscopic study, the entire skeletal duct system being obscured by alveolar development. Upon section, the gland was observed to be composed of a compact mass of tissue consisting for the most part of spherical alveoli lined with a single layer of cuboidal epithelial cells. The lumina of the alveoli are small, but are filled with secretion. The

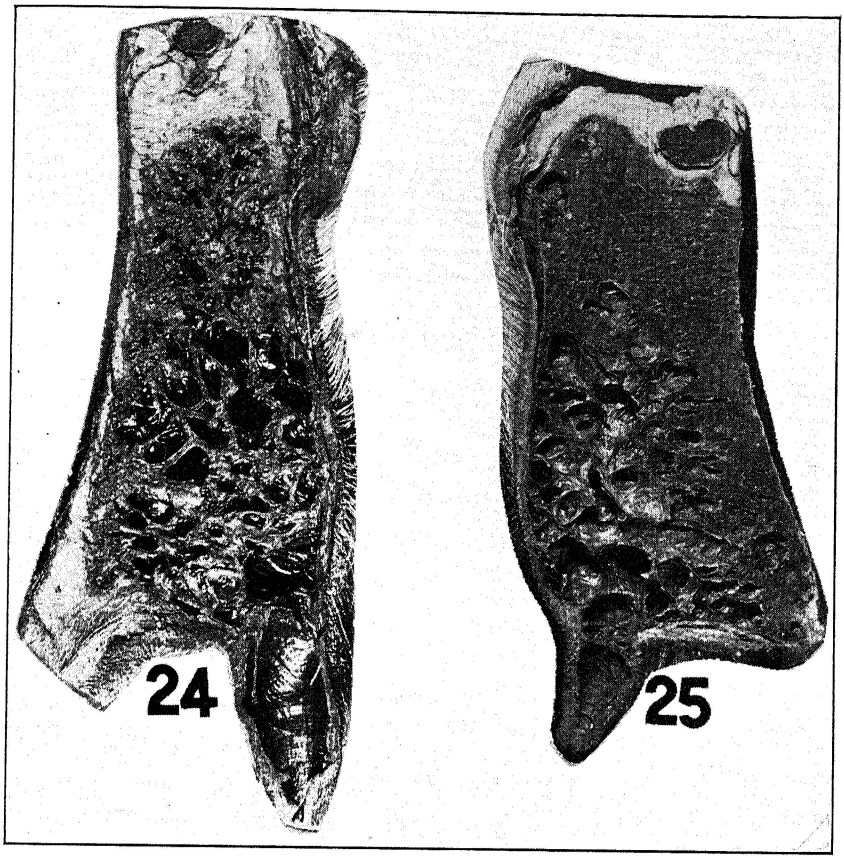

PLATE VI

Fig. 24.—Goat udder 108 days after conception. The udder is greatly enlarged and the lumina of the cistern of the teat and gland as well as the large ducts are greatly distended. This animal was a precocious milker and the type and extent of the development of glandular element is somewhat abnormal. (x½).

Fig. 25.—Goat udder 145 days after conception. The gland is very markedly hypertrophied due to the accumulation of secretion which is rapidly increasing at this stage (x½).

alveoli and larger divisions of the gland are enveloped in thin sheaths of connective tissue (Figs. 23 and 30).

In a series of experimental animals previously examined, it was observed quite uniformly that the greater part of the proliferation of the lobule-alveolar system occurred during the first half of pregnancy. This was inferred from the observation of large numbers of more or less compact alveoli present at that stage. It should not be assumed from this generalization that some increase in cell number of the individual alveoli does not occur. In fact, a few mitotic cells may be observed

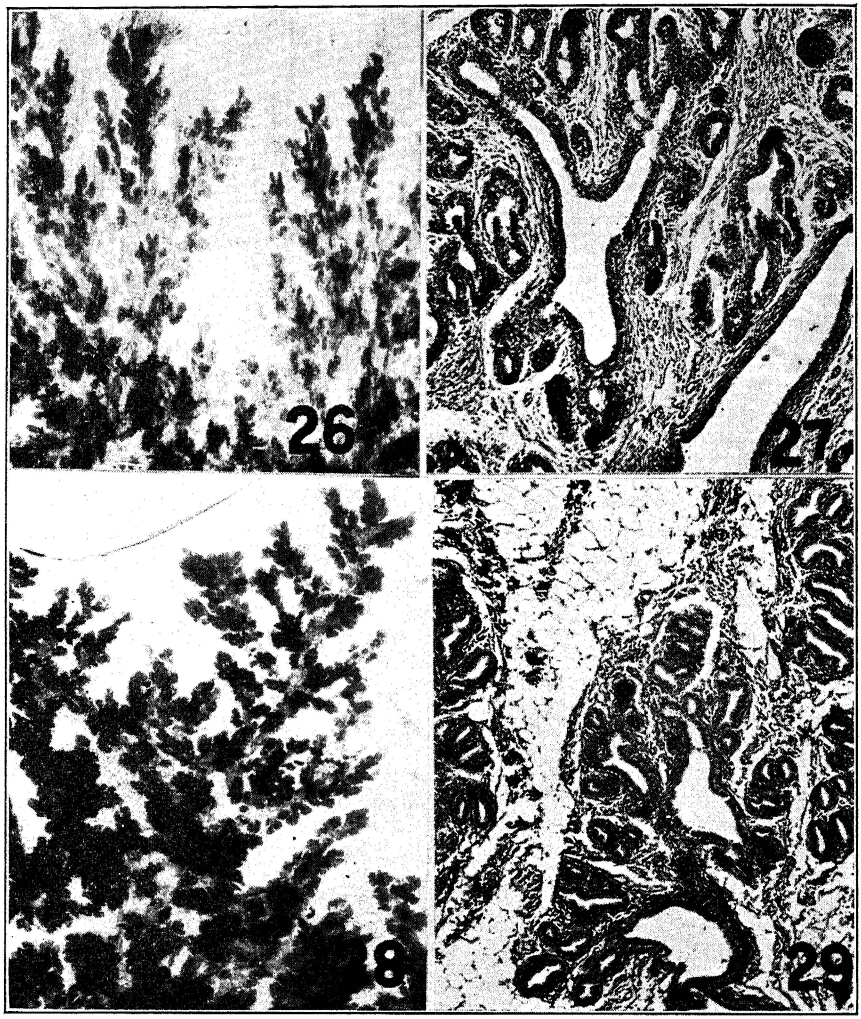

PLATE VII

Fig. 26.—Whole mount of a portion of the dissected mammary gland of a goat 25 days after conception. Note the great number of lateral buds arising from all planes of the main ducts which might be taken for a lobule-alveolar system. (x4).

Fig. 27.—Microphotograph of a section of the mammary gland shown in Fig. 26. It is evident that the peripheral region of this gland consists of ducts. (x30).

Fig. 28.—A whole mount of a portion of the dissected mammary gland of a goat 37 days after conception. A further multiplicity of lateral outgrowths has occurred. (x4).

Fig. 29.—Microphotograph of a section of the mammary gland shown in Fig. 28. Note that the periphery of the gland is still composed of duct elements. Alveolar elements at this atage are present in the region of the older ducts close to the base of the teat. (x30).

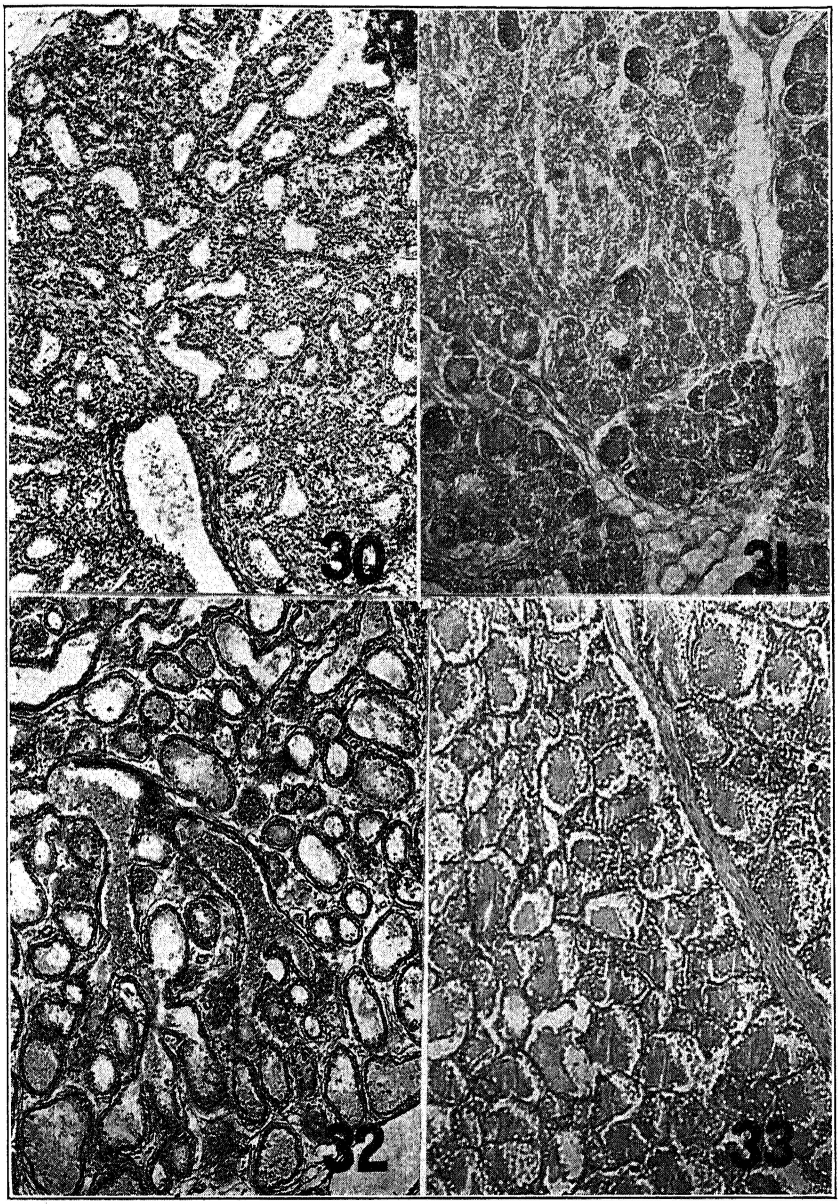

PLATE VIII

Fig. 30.—Microphotograph of a section of the mammary gland of an 88-day pregnant goat. At this stage the mammary gland growth is complete as indicated by the presence of the alveoli and the beginning of slight secretion. (x30).

Fig. 31.—Section of the mammary gland of a goat pregnant 108 days. The alveoli are further distended with secretion. (x30).

Fig. 32.—Section of the mammary gland of a goat pregnant 145 days. (x30).

Fig. 33.—Section of the mammary gland of a goat in an advanced stage of lactation. (x30).

throughout pregnancy. The writers are convinced from their observations that the rapid proliferation of the lobule system, involving the formation of the multitudinous alveoli, occurs in large part during the first half to two-thirds of pregnancy. While a slight multiplication of epithelial cells may occur during the latter part of pregnancy, the characteristic change in sections obtained after 108 and 145 days was a gradual increase in the lumina of the alveoli resulting from an accumulation of secretion. The secretion of milk in preparation for parturition was especially marked during the last week or ten days (Figs. 24, 25, 31 to 33).

V. LACTATION AND INVOLUTION

While normal lactation occurs only at the end of parturition, there are large numbers of cases of precocious or abnormal lactation in kids soon after birth, during the pubertal period and in older non-pregnant animals. Even in males, the number of cases of lactation is surprisingly large. It is believed to be desirable, therefore, to review these cases in the light of our present knowledge of the endocrinology of milk secretion. This study will be presented in another publication.

A study has been made of the involution of the mammary gland of the goat by Turner and Reineke (1936) to which the reader is referred.

SUMMARY AND CONCLUSIONS

The embryonic differentiation of the mammary apparatus in the dairy goat was first observed at the 25th day stage (0.5 cm. crown-rump length) as a light streak extending from the anterior to the posterior limb buds in the region of the ventro-lateral limiting furrow. This stage is believed to represent an early mammary streak. The mammary line stage was not observed.

At points on the mammary lines corresponding to the position of the future udder new centers of cell proliferation cause slight spherical elevations to appear called mammary crests. These structures begin to invaginate into the underlying tissue as cellular proliferation proceeds, forming half moon shaped mammary hillocks. It is probable that the fully rounded out mammary bud stages are reached when the embryos are about 3.0 cm. long. This stage was still present in 6.0 cm. male embryos.

The next important stage of development is initiated by the growth of the primary sprout from the mammary bud and the simultaneous proliferation of the mesenchyme tissue surrounding the bud to form the teat. The primary sprout starts to grow some time before the embryo reached the 11.4 cm. stage for at that time the sprout extended a considerable distance into the teat. By the 88th day (22.9 cm.), the primary

sprout had become transformed into the cistern of the teat and gland and numerous secondary sprouts had developed, some of which were already canalized to form the primary ducts.

During the period from 108 to 150 days of fetal life, the duct system develops considerably. Numerous branches of the chief ducts appear as well as lateral sprouts from the duct walls. These bud or sprout-like outgrowths are believed to be true ducts and not the precocious development of an alveolar system.

At birth the udder of the goat consists of a cistern and duct system which extends only a short distance into the fatty tissue of which the udder is composed. The mammary gland throughout the prepubertal period remains the same except for the increase in extent and degree of arborization of the ducts. The multiplicity of small branches may appear as alveoli unless carefully examined in sections and whole mounts.

In the male glands after birth, the rate of growth of the duct system is extremely slow. Even after several years of development the glands extend only slightly beyond the base of the teats.

With sexual maturity and the recurrence of estrus cycles the duct system continues to grow, resulting in the formation of numerous bud-like outgrowths in various planes of the lateral walls and the free ends of the ducts. The ducts so formed may be considered as a stage of lobule development but the formation of true alveoli was not observed in nulliparous females.

The growth of the udder during pregnancy in the goat was observed to be similar to that observed in a series of mammals previously examined. During the first half of pregnancy, the greater part of the proliferation of the lobule-alveolar system takes place whereas during the latter part the characteristic change was a gradual increase in the size of the lumina of the alveoli resulting from an accumulation of secretion.

The enlargement of the udder during the last week or ten days was especially marked.

LITERATURE CITED

Asdell, S. A. 1929 *Variation in the duration of gestation in the goat.* J. Agri. Sci., vol. 19, p. 382.

Bourdelle, E. et Bressou, C. 1929 *Etude des organes genitaux d'un buoc a mamelles.* Acad. Vet. de France. T. 82, p. 354.

Brouha, Dr. 1905 *Recherches sur les diverses phases du developpement et de l'activite de la mamelle.* Archives de Biologie. T. 21, p. 470.

Christ, F. 1905 *Untersuchungen uber die Muskulatur und das elastische gewebe in der Milchdrüse der Haussäugetiere.* Inaug. Diss. Giessen.

Elliott, R. H., Hall, F. G., and Hugget, A. St. G. 1934 *The blood volume and oxygen capacity of the foetal blood in the goat.* J. Physiol., vol. 82, p. 160.

Gardner, W. U., Gomez, E. T., and Turner, C. W. 1935 *Further studies of the effects of the estrogenic and the galactopoietic hormones upon the mammary gland of the rabbit.* Am. J. Physiol., vol. 112, p. 673.

Gisler, E. 1922 *Die Entwicklung der Milchdrüse bei der Katze.* Inaug. Diss. Zurich.

Hamburger, C. 1900 *Studien sur Entwickelung der mammarorgane. I. Die Zitze von Pferd un Esel.* Anat. Anz. Bd. 18 S. 16.

Henneberg, Brunno. 1900 *Die erste Entwickelung der Mammarorgane bei der Ratte.* Anat. Hefte. Bd. 13, S. 1.

Hirschland, L. 1899 *Beitrage zur ersten Entwickelung der Mammarorgane beim Menschen.* Anat. Hefte. Bd. 11, S. 221.

Käeppeli, F. 1918 *Ueber zitzen-zisternenverhaltnisse der Haussaugetiere.* Inaug. Diss Zurich.

Kiebel, F. 1897 *Normentafel zur Entwickelungsgeschichte des Schweines.* Jena.

Kupfer, Max 1928 *The sexual cycle of female domesticated mammals. The ovarian changes and the periodicity of oestrum in cattle, sheep, goats, pigs, donkeys, and horses.* Union of So. Africa Dept. of Agr. 13th and 14th Ann. Report Director of Vet. Education and Research, Part II, p. 1211.

Klaatsch, H. 1884 *Zur Morphologie der Saugethierzitzen.* Morphol. Jahrb., Bd. 9 S. 253.

Lustig, Hilda, 1916 *Zur Entwicklungesgeschichte der menschlichen Brustdruse.* Arch. f. Mikr. Anat., Bd. 87, S. 38.

Myers, J. A. 1917 Studies on the mammary gland. *II. The fetal development of the mammary gland of the female albino rat.* Am. J. Anat., vol. 22, p. 195.

Myers, J. A. 1917 Studies on the mammary gland. *III. A comparison of the developing mammary glands in the male and female albino rats from the late fetal stages to ten weeks of age.* Anat. Rec., vol. 13, p. 205.

Profe, O. 1899 *Beitrage zur Ontogenie und Phylogenie der Mammarorgane.* Anat. Hefte. Bd. 11, S. 247.

Rein, G. 1881-82 *Untersuchungen uber die embryonale Entwicklungsgeschichte der Milchdruse.* Archiv. f. Mikr. Anat., Bd., 20, S. 431 and Bd. 21, S. 678.

Shaw, E. L. 1934 Milk Goats. U. S. D. A. Farmers Bul. 920 (issued in 1918, revised Dec. 1927 and slightly revised March 1934).

Schikele, G. 1899 *Beiträge zur Morphologie und Entwicklung der normalen ünd überzahligen Milchdrusen.* Zeits. f. Morphol. und. Anthrophol. Bd. 1, S. 702.

Schultze, O. 1892 *Ueber die erste Anlage des Milchdrüsenapparates.* Anat. Anz., Bd. 7, S. 265.

Turner, C. W. 1930 The Anatomy of the mammary gland of cattle. *I. Embryonic development.* Mo. Agr. Exp. Sta. Res. Bul. 140.

Turner, C. W. 1931 The anatomy of the mammary gland of cattle. *II. Fetal development.* Mo. Agr. Exp. Sta. Res. Bul. 160.

Turner, C. W. 1936 *Seasonal variation in the birth rate of the milking goat in the United States.* Journ. Dairy Sci. (in press).

Turner, C. W., and Gomez, E. T. 1933 *The normal development of the mammary gland of the male and female albino mouse.* Mo. Agr. Exp. Sta. Res. Bul. 182.

Turner, C. W. and Gomez, E. T. 1934 *The normal development of the mammary gland of the male and female guinea pig.* Mo. Agr. Exp. Sta. Res. Bul. 194.

Turner, C. W. and Reineke, E. P. 1936 *A study of the involution of the mammary gland of the goat.* Mo. Agr. Exp. Sta. Res. Bul. 235.

UNIVERSITY OF MISSOURI COLLEGE OF AGRICULTURE

Agricultural Experiment Station