

## Answer to the ECG Dilemma

Sudarshan Balla<sup>1</sup>

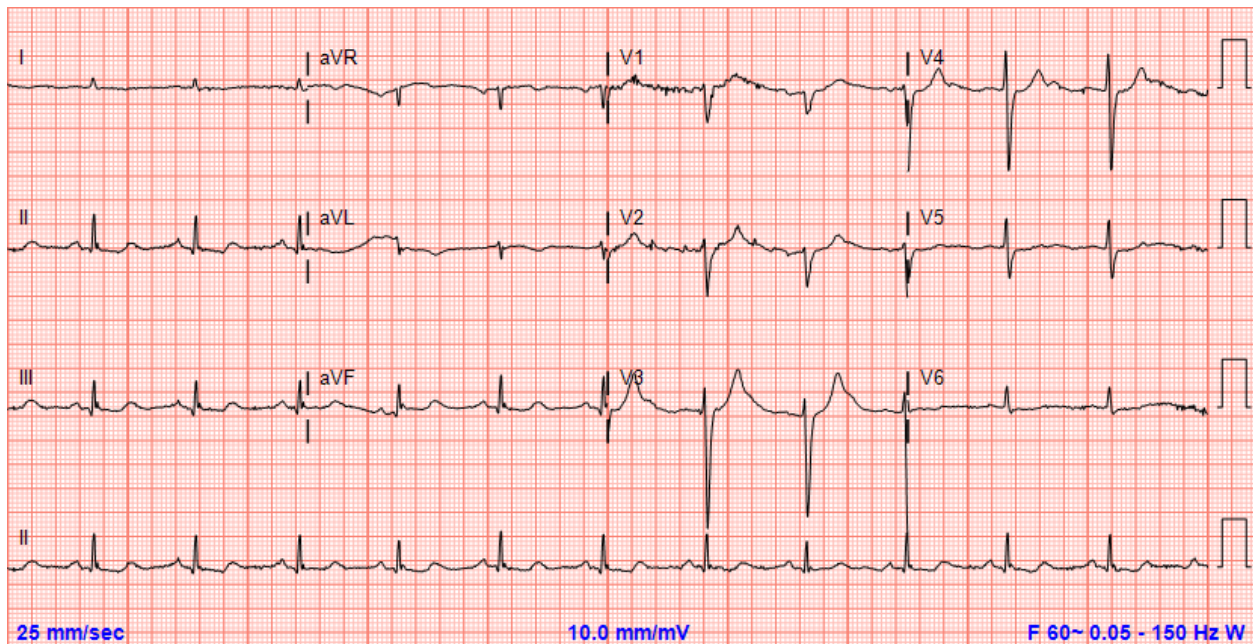
<sup>1</sup>Division of Cardiovascular Medicine, Department of Medicine, University of Missouri Health Care, Columbia, MO

Correspondence: Sudarshan Balla (ballas@health.missouri.edu)

Received March 26, 2017; accepted March 27, 2017

### Answer: 5

ECG shows evidence of severe hyperkalemia. There is widening of QRS and absent P wave which are seen with serum potassium  $> 7$  mEq/L. Left untreated, this can lead to ventricular fibrillation. Patients with ECG changes from hyperkalemia should be emergently treated with calcium gluconate for membrane stabilizing effect on cardiomyocytes to prevent arrhythmias. This should be followed administering sodium polystyrene sulfonate (Kayexalate®) and/or dextrose insulin infusion to lower the serum potassium. The use of NSAIDs in this patient with chronic kidney disease is the likely cause of significant hyperkalemia. ECG performed after resolution of hyperkalemia is shown below.



ECG courtesy of Mary Dohrmann MD