Artful Medicine

Story by Chris Blose
Images courtesy of Yash Sethi

Radiologists and technologists create images that illuminate, instruct and sometimes help save lives.

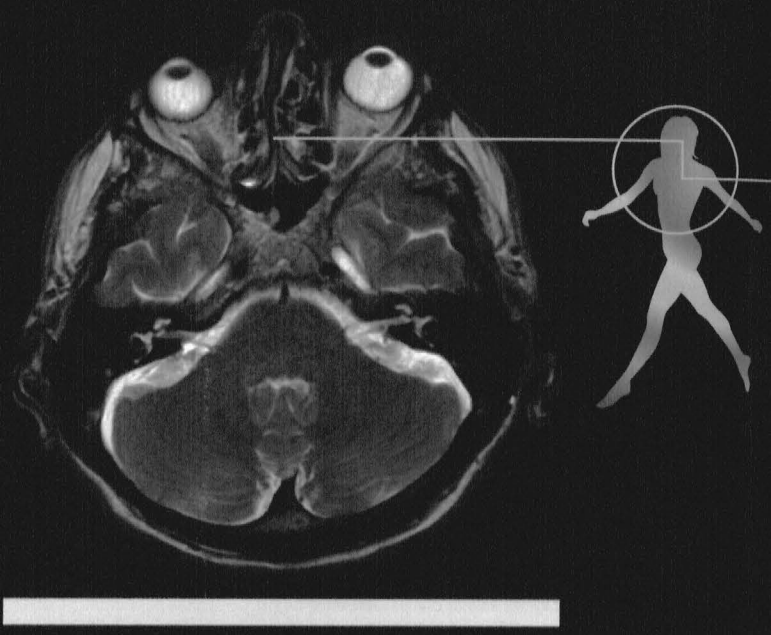

The lower levels of the building buzz with activity. People stare at images and scrutinize them. They talk about contrast and clarity. They point to fine details. They interpret and discuss exactly what the images mean.

As much as it may sound like it, this is no art gallery or workshop, and the people at work are not artists. At least not in the traditional sense. They are radiologists and technologists at University Hospital.

The images in question — scans of various body parts — help doctors diagnose disease and injury and pinpoint exactly where and what they are. Like masterful works of art, such medical images can evoke sadness, uncertainty, anger and, in the best cases, hope.

And like practiced artists, the people who create and interpret these images seek perfection. "When I get a perfect image, that makes my day," says Yash Sethi, an assistant professor and radiologist. "It makes my life easier in interpreting the image, making a decision and telling another doctor, 'Hey, this is what's wrong.' "

In that search for perfection, technology makes the difference. "The doctors are the same," Sethi says. "The buildings are the same. What's changed is the technology."

The following are but a few examples of that technology and the images it produces.

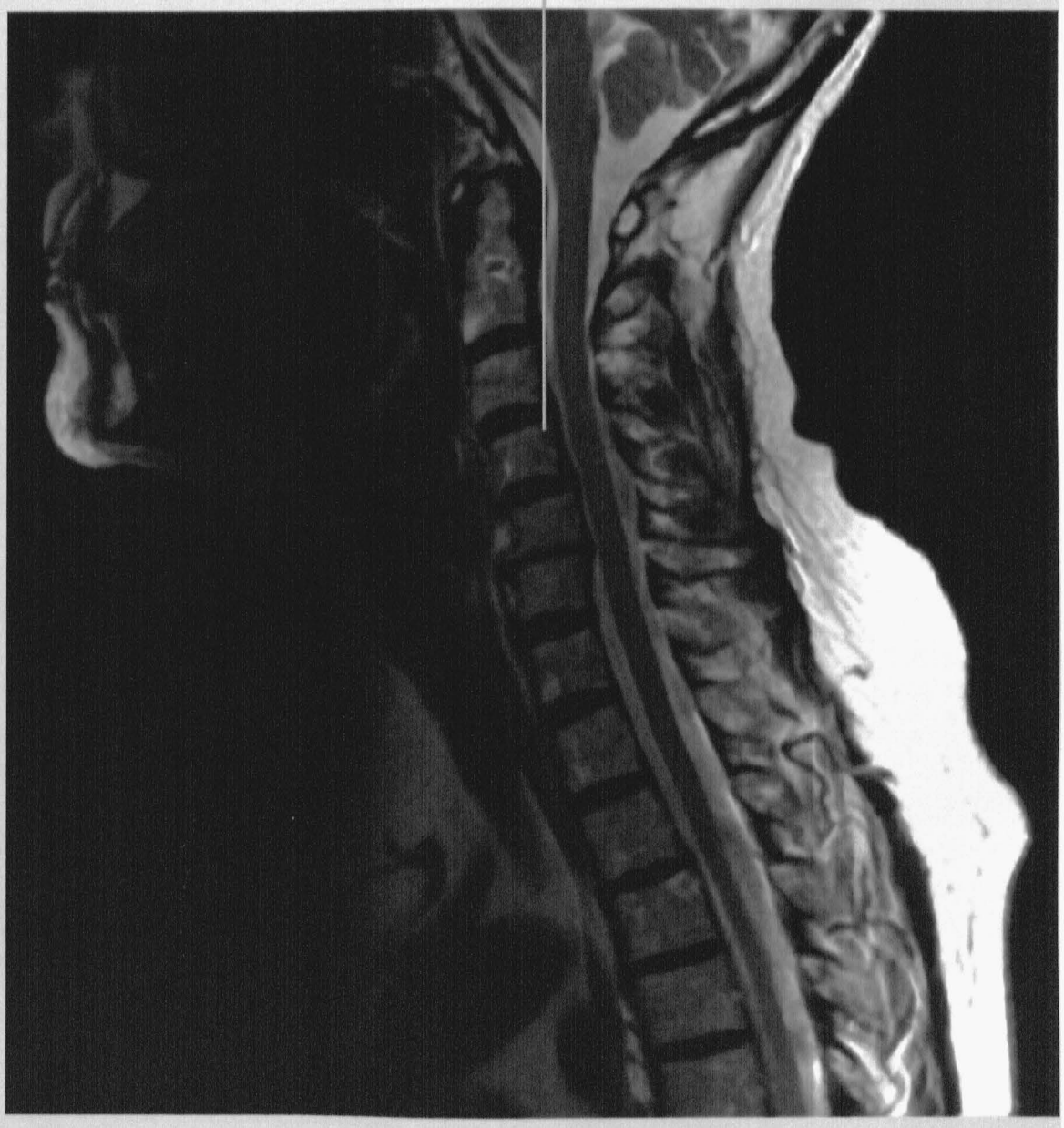

These are examples of Magnetic Resonance Imaging (MRI). MRI uses a big magnet to align the protons in the body. Then it sends out a radio pulse to measure the density of those protons. The density varies in different parts of the body. A computer then "back-constructs" the images. This technique shows all kinds of tissue in detail and with contrast. Doctors use MRI to detect heart disease and blood vessel blockage, stroke, cancer, injuries, and any number of other diseases and disorders. At top is a modified form of MRI, an angiogram, that shows the blood vessels in the brain. At right is a cervical spine image showing vertebrae, nerves and more. Above left is a horizontal slice of the head showing parts of the eyeballs, nerves and brain stem. "There's no other imaging modality that allows us to look at so many things at once," says radiologist Yash Sethi.

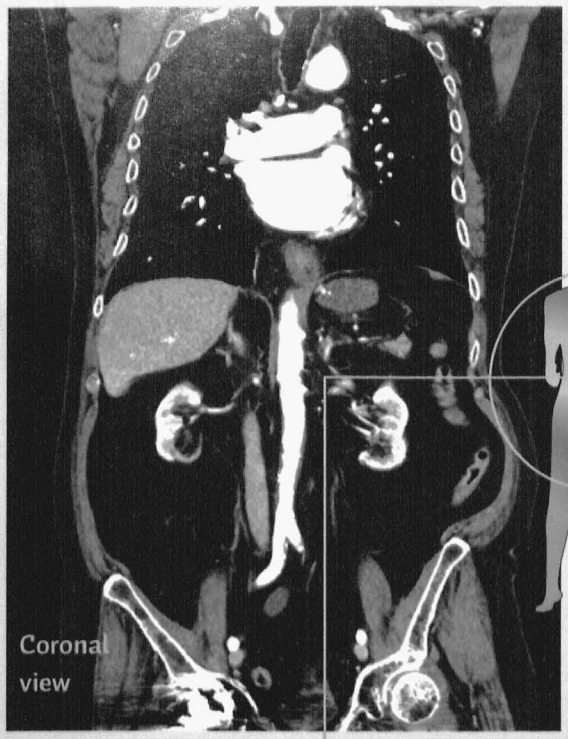

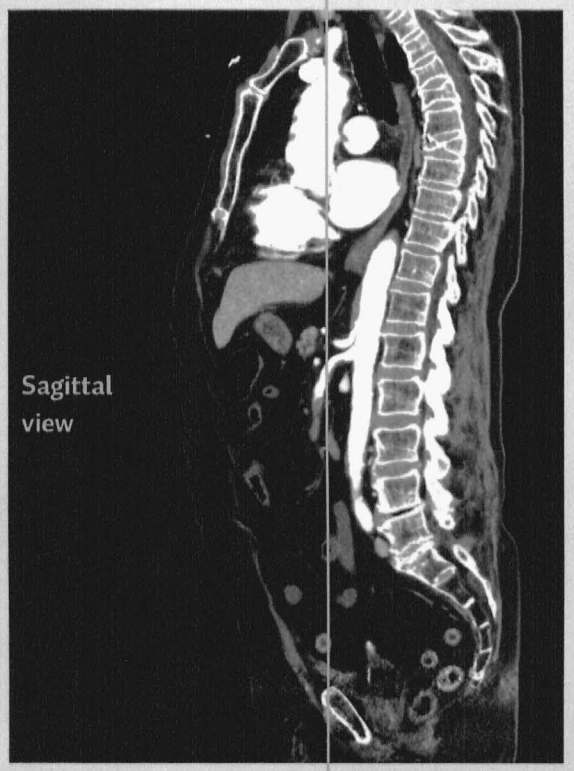

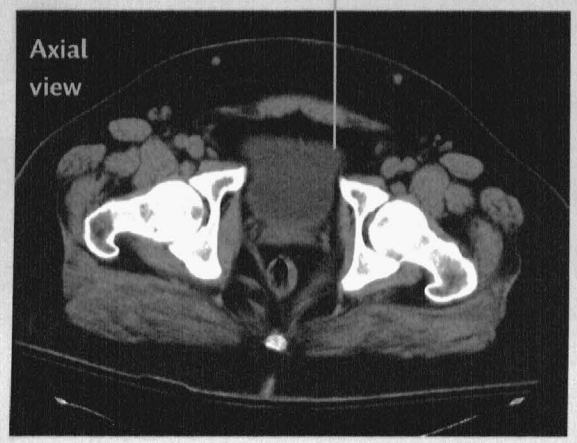

These images are various forms of computed tomography (CT), also known as CAT scans. CT uses X-rays in rotation around the body to produce anatomical slices. Doctors can use these slices on their own for internal detail, or they can stack them for a 3-D image.

Above is an example of those slices stacked to form a "pilot view" that radiologists would use to cross-reference exactly where in the body the various slices are. At left are CTs from the three basic views: coronal (from the front), sagittal (from the side) and axial (from the top).

The colorized image at right shows what radiologists get by putting all the slices of CT together to create a 3-D image. Each type of tissue — bones, kidneys, blood vessels and more — has its own color, so a surgeon can use such an image for precise guidance in diagnosis and treatment.

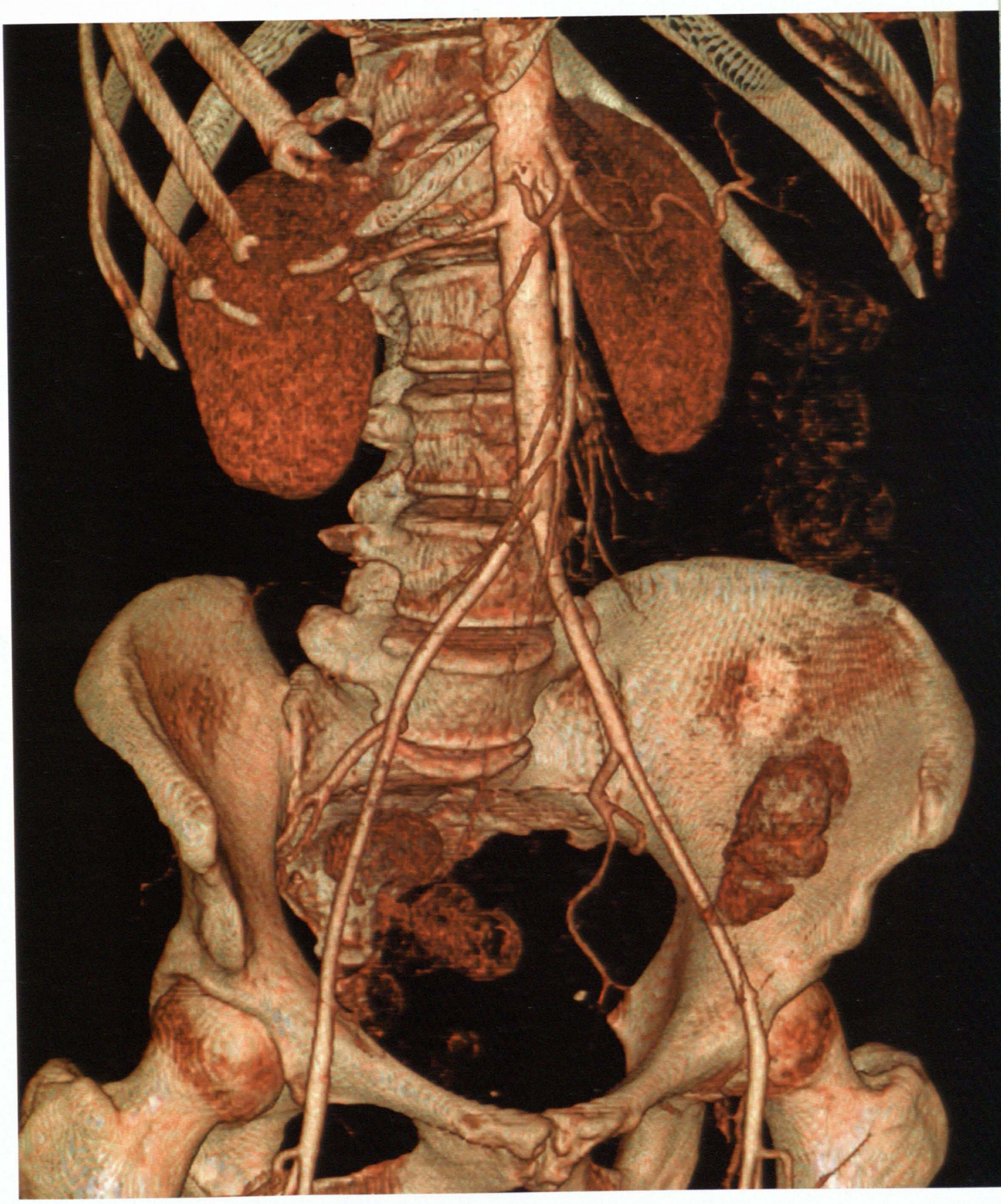

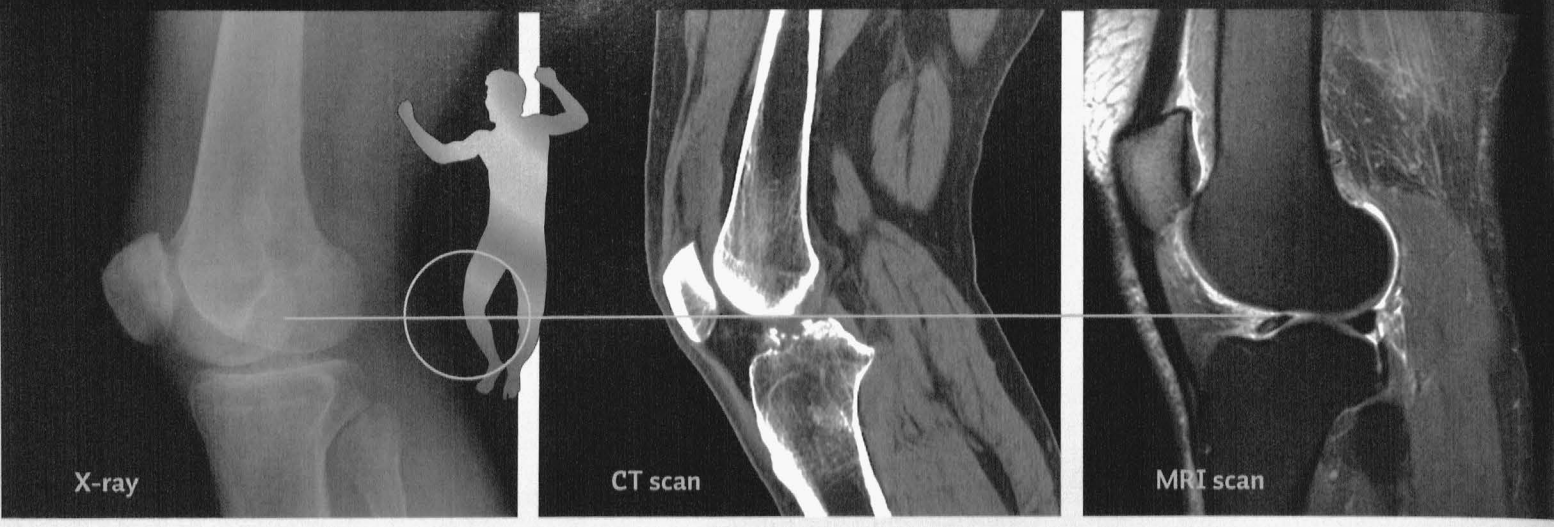

Above is a bit of the evolution of medical imaging. The image on the left is an X-ray, a quick and useful tool, especially when looking at bones. The problem is that it is only a 2-D view of the knee, so you can't find precisely where an injury is. The middle image comes from CT, which shows a slice inside the knee for easier and more exact diagnosis. The most time-consuming and complex kind of image is the MRI on the right. When it is necessary, MRI is the best of the three because it allows a doctor to see not only bone and hard structures but also muscle, ligaments, tendons and other forms of soft tissue.

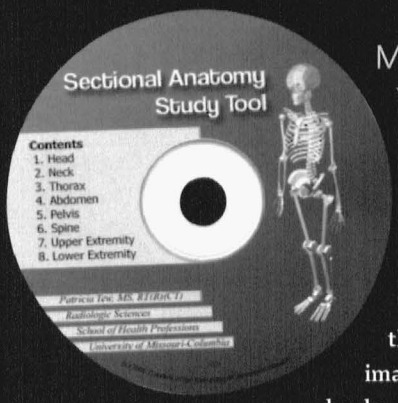

Medical art appreciation

When Pat Tew shows a crystal clear scan of a uterus on her computer screen, complete with labels for teaching, her enthusiasm shines through. "That's so cool," she says.

Tew, a professor in MU's School of Health Professions, is excited because she has created a powerful new teaching technique: the Sectional Anatomy Study Tool. It's an interactive computer program that teaches students both anatomy and how to read radiologic images. It's a supplement to resource carts full of massive anatomy books. Students can search through images of the entire body in cross sections and from the three traditional views: axial, coronal and sagittal.

The best part, Tew says, is that the interactive nature of the tool helps students learn to identify what they are seeing: "I never give them the answers. A lot of times, if they can scroll back and forth, they can discover what it is without even looking at the labels."

The images at right represent the next step in medical imaging, says Amolak Singh, director of nuclear medicine. It's called "fusion technology" because it fuses CT with Positron Emission Tomography (PET). "For diagnosing cancer, you need sensitivity," Singh says. "You need a test that's able to detect disease or cancer even when it's early." PET scans do that. Radiologists use a "tracer" in the body that lights up to show metabolic activity, or energy usage. Organs show this activity, but so do tumors as they are growing, so even the smallest ones will show up in a PET scan. The problem? It's sometimes hard to tell exactly where that cancer is. CT shows anatomy in more detail, so when you put the two together in PET CT, you can illuminate cancer and pinpoint it. From the left are CT scans, PET scans and then fused images. The hospital has yet to acquire the latest integrated PET CT machine. For now, Singh reads scans taken from a mobile unit and sometimes fuses separate CT and PET scans himself.

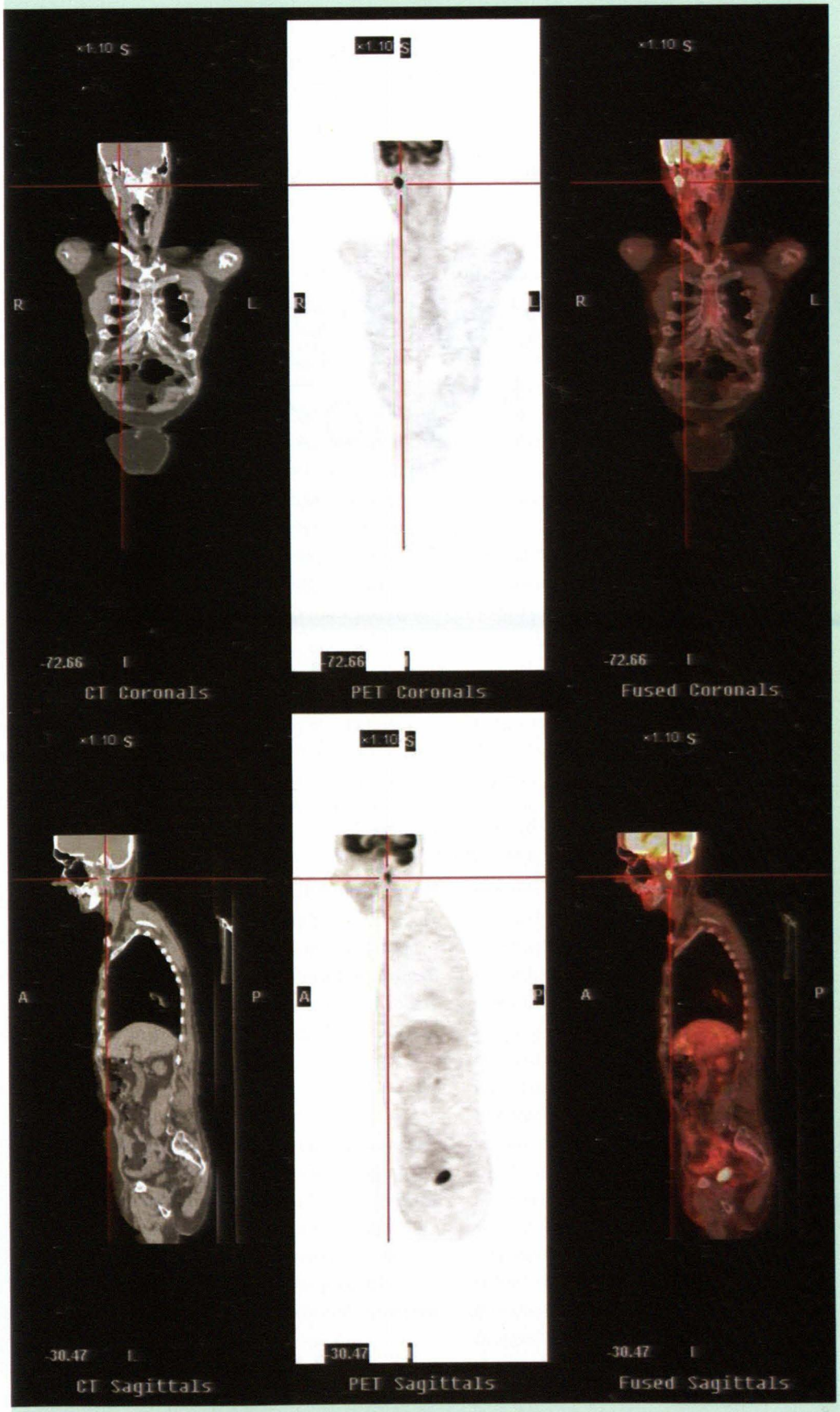

Images courtesy of Amolak Singh