



Sentinel Lymphadenectomy is Indicated for Staging Thin Melanoma with Regression



Nicole Shen, BS; Michael B. Nicholl, MD; Paul S. Dale, MD

ABSTRACT:

Introduction: Evidence of tumor regression may be found in 10-35% of cutaneous melanomas. Commonly, patients are offered Sentinel Lymph node Biopsy (SLNB) when regression is present. This practice has been challenged by reports which indicate LN metastasis risk is dependent primarily upon tumor depth, not the presence of regression. Our aim was to assess regression as a risk factor for nodal metastasis in the cohort of melanoma patients treated at Ellis Fischel Cancer Center.

Materials and Methods: To review our experience of primary melanoma with regression at the University of Missouri we performed a ten-year retrospective analysis (2000-2009).

Results: Of 192 patients (aged 23-89) with primary cutaneous melanoma, 11 (6%) had evidence of regression. The median Breslow depth of regressed tumors was 0.87 mm. (range 0.37-1.8) and the median Clarks level was 3 (range 2-4), only 3 patients had tumors >1.0mm (1.1,1.1, and 1.8 mm). There were no cases of recurrence in any of the patients which were followed for a median of 17 months (range 5-103 months). There were no melanoma related deaths. Of the patients with regression, 2/11 (18%) patients were found to have nodal metastasis; both had melanomas <1mm in depth. Neither of these primary melanomas with regression had poor prognostic factors, specifically no ulceration, angiolymphatic invasion or high mitotic index.

Conclusion: Our data indicate a high rate of nodal involvement in thin melanoma with regression. This finding conflicts with recent literature which suggests regression is not a risk factor for lymph node involvement in thin melanoma. Thorough clinical and pathologic evaluation of all melanoma patients should be performed and sentinel node biopsy should be considered in patients with evidence of regression especially if there is evidence of ulceration and mitotic figures identified in the primary lesion.

INTRODUCTION:

- >When there are no risk factors present, patient with melanoma <1mm (thin melanoma) are not routinely offered SLNB because the rate of LN metastasis is very low (3-5%).
- >Regression as a risk factor for LN metastasis in thin melanoma is controversial. Recent reports suggest prognosis in patients with regression is dependent upon depth at diagnosis, regardless of regression, therefore SLNB should not be routine for thin melanoma with regression

METHODS/MATERIALS:

- >A systemic search of the Ellis Fischel pathology records was used to obtain all pathology-documented cases of melanoma between 2000-2009.
- >These charts were reviewed for documentation of melanoma with evidence of regression.
- >The pathology reports of patients with evidence of regression were analyzed, noting each patient's gender, age, primary tumor location, median Breslow depth, Clarks level, tumor size, evidence of ulceration, angiolymphatic involvement, and mitotic figures.
- >Patients' electronic and chart medical records were analyzed to obtain information regarding SLNB, axillary dissection, and regional metastasis in follow-up.

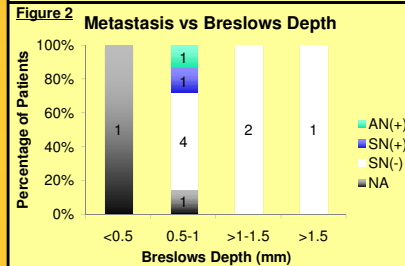
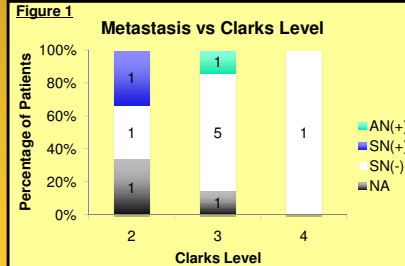


Figure 3

Cohort Data	Value	Range
Median Age	54	38-78
Median Clarks Level	3	2-4
Median Depth	0.87 mm	0.37-1.8 mm
Truncal	64.0%	
Extremity	27.0%	
Head and Neck	9.0%	
Ulceration	9.1%	
Angiolymphatic Involvement	0.0%	
Minimal to no Mitotic Figures	45.5%	
Positive SLNB	12.5%	
Positive Axillary Dissection	50.0%	
Positive Nodal Metastasis	18.2%	
Median Follow	17 months	5-103 months

RESULTS:

- > Of 192 patients (aged 23-89) with primary cutaneous melanoma, 11 (6%) had evidence of regression in the primary lesion. The regression group was composed of 6 men and 5 women with a median age of 54 (range of 38-78). In the regression group, primary tumors were truncal in 7 patients (64%, 4 female, 3 male), extremity in 3 patients (27%, 2 female, 1 male) and head/neck in 1 patient (9%, 1 male).
- >The median Breslow depth of tumors with regression was 0.87 mm. (range 0.37-1.8) and only 3 patients had intermediate thickness tumors (1.1,1.1, and 1.8 mm). The median Clarks level was 3 (range 2-4) (Figure 1, 2). On pathologic evaluation, 1/11 had evidence of ulceration, no angiolymphatic involvement was identified, and 6/11 had mitotic figures identified (Figure 3).
- >One patient presented with a positive axillary dissection (1/11 nodes). Of 8 patients who underwent SLNB, 1/8 (12.5%) had a positive SLNB with no additional positive nodes on completion axillary dissection (1/23). The patients with regression and node positive disease had primary tumor thickness of 0.77 and 0.89 mm, no ulceration, and 0 and 5 mitotic figures/10hpf respectively. Two patients had no evaluation of their regional lymph nodes and had no clinical evidence of regional metastasis in follow-up (Figure 1, 2).
- > There were no cases of recurrence in any of the patients with regression (median follow-up 17 months (range 5-103 months)). There were no melanoma related deaths, 2 patients died of non-melanoma related illnesses.

CONCLUSIONS:

- >Our data indicate a high rate of nodal involvement in thin melanoma with regression.
- >Mitotic index was not a risk factor for LN metastasis in thin melanoma with regression.
- >Our findings conflict with recent literature which suggests regression is not a risk factor for lymph node involvement in thin melanoma.
- >Thorough clinical and pathologic evaluation of all melanoma patients should be performed and SLNB should be considered in patients with evidence of regression especially if there is evidence of ulceration and identified in the primary lesion.

REFERENCES:

Requena, C.; Bolella-Estrada, R.; Traves, V.; Nagora, E.; Almenar, S.; Guillen, C. *Actas Dermosifiliogr* 2009, 100(9), 759-766.
Mays, M. P.; Martin, R. C.; Burton, A.; Ginter, B.; Edwards, M. J.; Reintgen, D. S.; Ross, M. I.; Urist, M. M.; Stromberg, A. J.; McMasters, K. M.; Scoggins, C. R. *Cancer*, 116(6), 1535-1544.
Cadli, A.; McKinnon, G.; Wright, F.; Hanna, W.; Macintosh, E.; Abhari, Z.; Dabbs, K. *J Surg Oncol*, 101(3), 191-194.