

CASE REPORT**Severe Hypothyroidism Presenting as Cardiac Tamponade**
Prutha Pathak,¹ Siddharth Patel,² Ashish Basu,² Mc Anto Antony³¹Gillings School of Global Public Health, University of North Carolina, Chapel Hill, NC, USA²Decatur Morgan Hospital, Decatur, AL, USA³Medical University of South Carolina/AnMed Campus, Anderson, SC, USA

Corresponding author: Siddharth Patel, Decatur Morgan Hospital, 1201 7th street SE, Decatur, AL, 35601
(spate101@alumni.jh.edu)

Received: 9/1/2022 Revised: 9/27/2022 Accepted: 10/7/2022 Published: 12/31/2022

Am j Hosp Med 2022 Oct;6(4): 2022. DOI: <https://doi.org/10.24150/ajhm/2022.017>

Keywords: Tamponade, Hypothyroidism, Pericardial effusion

ABSTRACT

Wide-spread availability of thyroid stimulating hormone assays and routine screening have resulted in early diagnosis of hypothyroidism. Affordable thyroid hormone replacement therapy has ensured that the prevalence of complications of untreated hypothyroidism including cardiovascular complications remains extremely low. Although pericardial effusion can be seen in hypothyroidism especially in severe cases, cardiac tamponade is uncommon. Cardiac tamponade as the first presenting feature of hypothyroidism is a rarity. A 60-year-old man with a history of hypertension and stroke was brought to the hospital with chief complaints of fall and altered mental status. In the emergency room, he was found to have hypothermia and drowsiness, and his laboratory investigations showed severe hypothyroidism. CT scan of chest revealed a large pericardial effusion and an echocardiogram showed evidence of cardiac

tamponade. He was taken for an emergent pericardiotomy with a pericardial window. Pericardial fluid and serum investigations confirmed untreated hypothyroidism as the cause of cardiac tamponade. The patient was treated with aggressive thyroid hormone replacement therapy and his clinical condition improved. This case highlights the importance of screening and treatment of hypothyroidism in at-risk populations. If untreated, hypothyroidism may rarely lead to a potentially life-threatening complication such as cardiac tamponade.

INTRODUCTION

Pericardial diseases present either as isolated disorders or as manifestations of systemic disorders. Pericarditis, pericardial effusion without hemodynamic compromise, cardiac tamponade and constrictive pericarditis are some of the clinical presentations of pericardial diseases. Pericardial effusion is asymptomatic in most cases unless the

amount of effusion is large enough to cause cardiac tamponade which could result in hemodynamic instability. Although pericardial effusion can be seen in hypothyroidism, cardiac tamponade rarely occurs as its presenting manifestation. Cardiac tamponade in severe hypothyroidism requires urgent medical and surgical management. The presented case provides a good review of this uncommon clinical entity.

CASE PRESENTATION

A 60-year-old morbidly obese Caucasian man with a history of tobacco smoking, hypertension and right parietal lobe stroke was brought to the hospital for a fall and altered mental status. He had increasing fatigue, recurrent falls and progressive hoarseness of voice for 2 months. In the Emergency Room (ER), he was found to be confused. His family reported non-compliance with medications. He smoked about 2 packs of cigarettes per day for 40 years. On examination, his temperature was 96.6 F, pulse 76/min, respiratory rate 15/min, blood pressure 128/86 mmHg and oxygen saturation 92% on room air. He was extremely drowsy. He had a puffy face and a dry oral cavity. On cardiovascular examination, S1 and S2 were regular but distant without any murmur, rub or gallop. Thyromegaly and jugular venous pulsations were difficult to assess due to a short neck with excessive fat deposition. Air entry was equal bilaterally without adventitious breath sounds. There was a healed scar of cholecystectomy on the right upper quadrant of abdomen. His abdomen was soft and

nontender. He did not have hepatomegaly, splenomegaly or ascites. Lower extremities had pitting edema extending up to upper legs bilaterally. Though he was arousable to verbal stimuli, he was not able to remain awake consistently during the encounter. He had residual weakness of the left upper and lower extremity with symmetric and intact sensations bilaterally. Knee, biceps and ankle reflexes were sluggish bilaterally. He was disoriented and had marked dysarthria and hoarseness. Skin was dry and scaly without hematoma or ulcer.

INVESTIGATIONS

Laboratory data revealed hyponatremia, hypochloremia, and rhabdomyolysis. Renal function tests and hepatic function tests were normal. Pro-B type Natriuretic Peptide and troponin were not significantly elevated. TSH was 100 mIU/mL and free T4 was 0.1 ng/dL. Arterial blood gas detected acute respiratory acidosis with hypercapnia (Table 1). Chest X-ray performed for mild hypoxia detected marked cardiomegaly. CT scan revealed a large pericardial effusion without thyromegaly (Figure 1) and EKG was remarkable for low voltage QRS. An urgent 2-D transthoracic echocardiogram (echo) was performed where a large circumferential pericardial effusion with early diastolic right ventricular wall collapse was seen (Figure 2). Left ventricle function was preserved. He was diagnosed with myxedema coma with pericardial effusion causing cardiac tamponade and emergently taken for pericardiocentesis with pericardial window procedure.

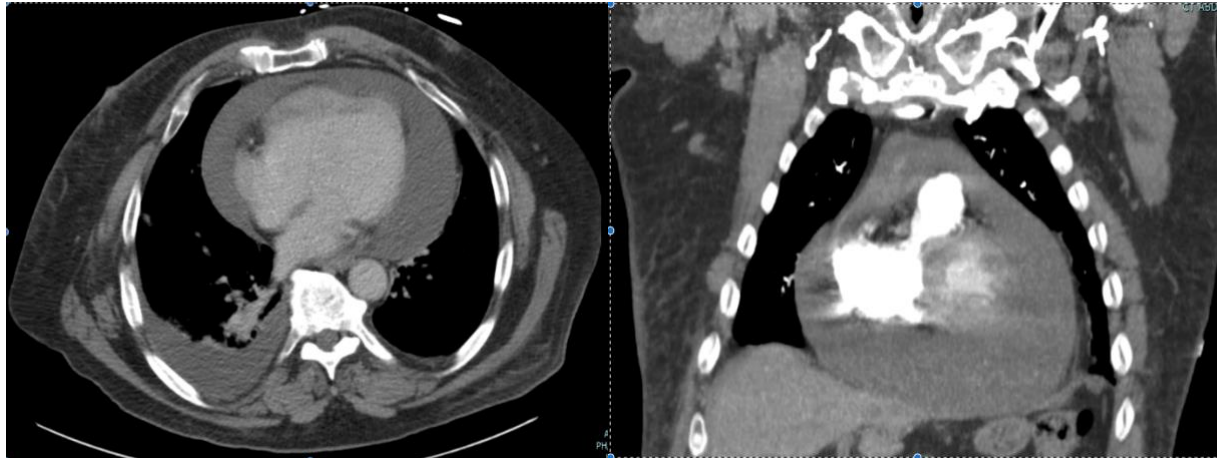


Figure 1: CT scan of chest showing marked pericardial effusion

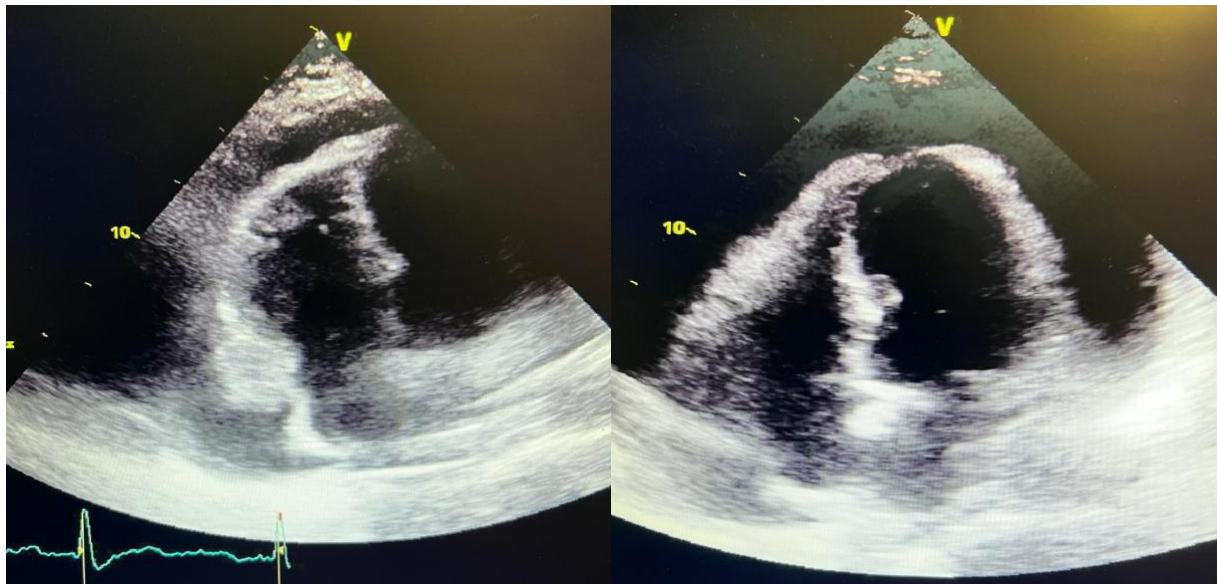


Figure 2: 2D Echo showing Echo-free space suggestive of pericardial effusion with diastolic collapse of right atrium and ventricle.

HOSPITAL COURSE

1300 ml of clear straw-colored fluid was removed during the pericardial window procedure. No obvious gross abnormality could be detected in the pericardium. Surgery was uneventful and the patient was transferred to the intensive care unit for

further management. Patient was started on thyroid replacement therapy with intravenous levothyroxine and enteral liothyronine. Respiratory support was provided through non-invasive positive pressure ventilation. Anti-Thyroid Peroxidase (anti-TPO) antibody titer came back significantly elevated (Table 1). Pericardial fluid

chemistry, culture, cytology and pericardial biopsy were unremarkable for infectious or neoplastic etiologies (Table 2). It was concluded that the patient had cardiac tamponade due to effusion resulting from undiagnosed Hashimoto's thyroiditis and severe hypothyroidism.

With thyroid replacement therapy, his alertness, hoarseness of voice and physical strength improved over the subsequent 7 days. Hypoxic hypercapnic respiratory failure improved after non-invasive positive pressure ventilation, and eventually the patient was able to maintain adequate oxygenation and ventilation with the use of a nasal cannula. With the downward trend of TSH (Table 1), he transitioned to oral levothyroxine therapy. He started participating in physical therapy and was eventually discharged to a rehabilitation facility.

DISCUSSION

Pericardium is a double-layered fibroelastic sac containing about 15-50 ml of plasma ultrafiltrate. Normal pericardium exerts a restraining force to prevent sudden dilation of cardiac chambers and maintains normal anatomic position of the heart. Pericardial effusion can result from pericarditis, malignancy, uremia, myocardial infarction, hypothyroidism, infection and trauma. However, the etiology remains idiopathic in many effusions.¹ Cardiac tamponade results when a large pericardial effusion impedes cardiac filling. Right-sided chambers are affected more due to their thin wall. The classic presenting symptoms of cardiac tamponade include hypotension, distant heart

sounds and neck vein engorgement (Beck's triad).² Sinus tachycardia is also commonly seen as a compensation to hypotension to allow for maintenance of cardiac output. Pulsus paradoxus with an exaggerated decrease in systolic blood pressure results from drastic decrease in left ventricular output during inspiration because of under-filling of the left ventricle.³ Pericardial rub may be auscultated if effusion is a result of inflammatory pericarditis.⁴

Patients suspected to have cardiac tamponade should be investigated with an electrocardiogram (EKG), a chest x-ray and an echo. EKG may detect sinus tachycardia, low voltage QRS complex and electrical alternans. Chest x-ray may reveal cardiomegaly. Diastolic collapse of the right atrium and right ventricle with a large pericardial effusion on echo confirms the diagnosis.⁵ In many cases, the fluid accumulation is very slow or chronic allowing the pericardial compliance to increase gradually. These effusions could remain asymptomatic for a long time. On the other hand, acute pericardial effusion e.g. from bleeding due to trauma into a relatively stiff pericardium can rapidly lead to cardiac tamponade.

Normal level of thyroxine is required for maintaining cardiac output and cardiac contractility.⁶ Hypothyroid patients generally have bradycardia, hypotension and reduced cardiac output.⁶ Hypothyroid cardiomyopathy is manifested by thickening of the interventricular septum and right ventricular wall as well as global dysfunction of the left ventricle.⁷ Pericardial effusion in hypothyroidism has been reported as early as 1918.⁸ It is estimated to affect 3-6% of

hypothyroid patients.⁹ According to a study published by Hardisty et al., out of 39 consecutive hypothyroid patients, 12 had pericardial effusion and only 1 of those had a large pericardial effusion.¹⁰ In hypothyroidism, the accumulation of effusion usually occurs very slowly, and therefore, cardiac tamponade is extremely rare. It is estimated that 2-5% of cardiac tamponade could be due to hypothyroidism.^{11,12}

The presentation of our patient was unique for multiple reasons. Firstly, severe hypothyroidism is now rare due to widespread availability of thyroid function assays and early diagnosis. In our patient, Beck's triad of cardiac tamponade was absent except for the presence of distant heart sounds. Due to severe hypothyroidism leading to neck and truncal adipose tissue deposition, jugular venous distension and thyromegaly were not evident. The patient did not have tachycardia and instead his heart rate was within normal range, which was thought to be due to a net effect of bradycardia that is commonly encountered in severe hypothyroidism. Hypoxia and hypercapnia due to poor ventilatory drive and decreased respiratory muscle strength associated with hypothyroidism respond well to thyroid replacement therapy as shown in our case. While EKG had a low voltage, it did not have classic electrical alternans despite the presence of a massive effusion.

Pericardial effusion in hypothyroid patients could improve with just thyroid replacement therapy.¹⁰ In fact, there have been case reports of resolution of tamponade with just medical therapy of hypothyroidism.¹³⁻¹⁵ However, it requires

close monitoring of hemodynamics with serial echo imaging. Massive pericardial effusion (e.g. about 1300 mL in this case) with tamponade generally requires urgent surgical intervention to prevent clinical deterioration. Many times, despite definitive surgical treatment, pericardial effusion recurs which requires close follow-up.¹⁶

Notes

Conflicts of Interest: None declared

Funding: None declared

Acknowledgements: None

Table 1: Blood investigations with reference ranges in parentheses

White Blood Cell count	4250 cells/microL (4000-11000 cells/microL)
Hemoglobin	12.8 g/dL (12-16 g/dL)
Platelet count	113,000 platelets/microL (130,000-400,000 platelets/microL)
Sodium	123 mmol/L (135-145 mmol/L)
Potassium	4.6 mmol/L (3.5-5 mmol/L)
Chloride	90 mmol/L (98-105 mmol/L)
Blood Urea Nitrogen	7 mg/dL (8-22 mg/dL)
Glucose	89 mg/dL (70-104 mg/dL)
Creatinine	1.0 mg/dL (0.5-0.9 mg/dL)
Calcium	9.3 mg/dL (8.8-10.2 mg/dL)
Creatinine Kinase	1778 U/L (24-173 U/L)
Troponin	85 ng/L (0-19 ng/L)
Pro-B type Natriuretic Peptide	172 pg/mL (5-226 pg/mL)
Aspartate Aminotransferase	76 U/L (10-36 U/L)
Alanine Aminotransferase	24 U/L (10-30 U/L)
Alkaline Phosphatase	74 U/L (32-104 U/L)
Albumin	4.4 g/dL (3.5-5 g/dL)

Bicarbonate	25 (22-28)
Total Protein	6.4 g/dL (6.3-8.3 g/dL)
TSH	100 mIU/L (0.4-4 mIU/L)
Free T4	0.1 ng/dL (0.9- 1.7 ng/dL)
Free T3	<1.0 pg/mL (2.6-4.4 pg/mL)
Anti-Thyroid Peroxidase antibody	473 IU/mL (<34 IU/mL)
pH	7.31 (7.35-7.45)
pO ₂	71 mmHg (60-100 mmHg)
pCO ₂	100 (35-45 mmHg)
TSH on Day 7 of admission	25.76 mIU/L (0.4-4 mIU/L)

Table 2: Pericardial fluid studies:

Glucose	98 mg/dL (80-134 mg/dL)
Total Protein	4.8 g/dL (1.7-4.6 g/dL)
Lactate Dehydrogenase	275 U/L (141-2600U/L)
Microbiology	No white blood cells, epithelial cells or bacteria
Histopathology of pericardium	Pericardial tissue with patchy chronic inflammation and edema
Cytology	Negative for malignancy

REFERENCES

1. Sagristà-Sauleda, J et al. "Clinical clues to the causes of large pericardial effusions." *The American journal of medicine* vol. 109,2 (2000): 95-101. doi:10.1016/s0002-9343(00)00459-9
2. Sternbach, G. "Claude Beck: cardiac compression triads." *The Journal of emergency medicine* vol. 6,5 (1988): 417-9. doi:10.1016/0736-4679(88)90017-0
3. Johnson, Sara K et al. "Adolf Kussmaul: distinguished clinician and medical pioneer." *Clinical medicine & research* vol. 7,3 (2009): 107-12. doi:10.3121/cmr.2009.850
4. Spodick, D H. "Pericardial rub. Prospective, Multiple observer investigation of pericardial friction in 100 patients." *The American journal of cardiology* vol. 35,3 (1975): 357-62. doi:10.1016/0002-9149(75)90027-2
5. Reydel, B, and D H Spodick. "Frequency and significance of chamber collapses during cardiac tamponade." *American heart journal* vol. 119,5 (1990): 1160-3. doi:10.1016/s0002-8703(05)80248-0
6. Klein, I. "Thyroid hormone and the cardiovascular system." *The American journal of medicine* vol. 88,6 (1990): 631-7. doi:10.1016/0002-9343(90)90531-h
7. Shenoy, M M, and J M Goldman. "Hypothyroid cardiomyopathy: echocardiographic documentation of reversibility." *The American journal of the medical sciences* vol. 294,1 (1987): 1-9. doi:10.1097/00000441-198707000-00001
8. Kopp, Peter A. "Das Myxödemherz: The Myxedema Heart Herman Zondek 1887-1979." *Thyroid : official journal of the American Thyroid Association* vol. 28,9 (2018): 1079-1080. doi:10.1089/thy.2018.0528
9. Kabadi, U M, and S P Kumar. "Pericardial effusion in primary hypothyroidism." *American heart journal* vol. 120,6 Pt 1 (1990): 1393-5. doi:10.1016/0002-8703(90)90253-t
10. Hardisty, C A et al. "Pericardial effusion in hypothyroidism." *Clinical endocrinology* vol. 13,4 (1980): 349-54. doi:10.1111/j.1365-2265.1980.tb03395.x
11. Sagristà-Sauleda, J et al. "Clinical clues to the causes of large pericardial effusions." *The American journal of medicine* vol. 109,2 (2000): 95-101. doi:10.1016/s0002-9343(00)00459-9
12. Ma, W et al. "Causes of moderate to large pericardial effusion requiring pericardiocentesis in 140 Han Chinese patients." *Herz* vol. 37,2 (2012): 183-7. doi:10.1007/s00059-011-3428-5
13. Hsieh, Chung-Yueh et al. "Massive pericardial effusion with diastolic right ventricular compression secondary to hypothyroidism in a 73-year-old woman." *Emergency medicine Australasia : EMA* vol. 23,3 (2011): 372-5. doi:10.1111/j.1742-6723.2011.01425.x
14. Butala, Ashvin et al. "Cardiac tamponade as a presenting manifestation of severe hypothyroidism." *BMJ case reports* vol. 2013 bcr2012005281. 5 Feb. 2013, doi:10.1136/bcr-12-2011-5281
15. Hsieh, Chung-Yueh et al. "Massive pericardial effusion with diastolic right

ventricular compression secondary to hypothyroidism in a 73-year-old woman.” *Emergency medicine Australasia : EMA* vol. 23,3 (2011): 372-5. doi:10.1111/j.1742-6723.2011.01425.x

16. Karu, Andrew K et al. “Impending cardiac tamponade as a primary presentation of hypothyroidism: case report and review of literature.” *Endocrine practice : official journal of the American College of Endocrinology and the American Association of Clinical Endocrinologists* vol. 11,4 (2005): 265-71. doi:10.4158/EP.11.4.265